

reviews

Major Pulmonary Embolism*

Review of a Pathophysiologic Approach to the Golden Hour of Hemodynamically Significant Pulmonary Embolism

Kenneth E. Wood, DO, FCCP

Major pulmonary embolism (PE) results whenever the combination of embolism size and underlying cardiopulmonary status interact to produce hemodynamic instability. Physical findings and standard data crudely estimate the severity of the embolic event in patients without prior cardiopulmonary disease (CPD) but are unreliable indicators in patients with prior CPD. In either case, the presence of shock defines a threefold to sevenfold increase in mortality, with a majority of deaths occurring within 1 h of presentation. A rapid integration of historical information and physical findings with readily available laboratory data and a structured physiologic approach to diagnosis and resuscitation are necessary for optimal therapeutics in this “golden hour.” Echocardiography is ideal because it is transportable, and is capable of differentiating shock states and recognizing the characteristic features of PE. Spiral CT scanning is evolving to replace angiography as a confirmatory study in this population. Thrombolytic therapy is acknowledged as the treatment of choice, with embolectomy reserved for those in whom thrombolysis is contraindicated. (CHEST 2002; 121:877–905)

Key words: echocardiogram; embolectomy; hemodynamics; pulmonary embolism; shock; thrombolytic therapy

Abbreviations: aPTT = activated partial thromboplastin time; CO = cardiac output; CPD = cardiopulmonary disease; CPR = cardiopulmonary resuscitation; CPP = coronary perfusion pressure; CXR = chest radiograph; DVT = deep venous thrombosis; ECHO = echocardiography; ICOPER = International Cooperative Pulmonary Embolism Registry; IVC = inferior vena cava; LV = left ventricular; MAP = mean arterial pressure; MAPPET = Management Strategy and Prognosis of Pulmonary Embolism Registry; mPAP = mean pulmonary artery pressure; MPE = major pulmonary embolism; NE = norepinephrine; PA = pulmonary artery; P(A-a)O₂ = alveolar-arterial oxygen pressure difference; PAP = pulmonary artery pressure; PCWP = pulmonary capillary wedge pressure; PE = pulmonary embolism; PEA = pulseless electrical activity; PIOPED = Prospective Investigation of Pulmonary Embolism Diagnosis; PVC = pressure venous capacitance; PVR = pulmonary vascular resistance; RA = right atrium; RAP = right atrial pressure; RBBB = right bundle branch block; rt-PA = recombinant tissue plasminogen activator; RV = right ventricle, ventricular; RVEDP = right ventricular end-diastolic pressure; SVR = systemic vascular resistance; TEE = transesophageal echocardiography; TR = tricuspid regurgitation; TTE = transthoracic echocardiography; UPET = Urokinase Pulmonary Embolism Trial; UK = urokinase; USPET = Urokinase Streptokinase Pulmonary Embolism Trial; VD/V_T = physiologic dead space ventilation; V/Q = ventilation/perfusion ratio; VR = venous return

Venous thrombosis is always a severe disease and is often fatal, because fragments of the thrombi may detach and occlude branches of the pulmonary artery. . . . the occlusion of the main branches of the pulmonary artery causes a striking rise of the blood pressure in these vessels. This

rise—which the right heart must fight in order to ensure circulation—may sometimes lead to cardiac arrest.

Picot 1884
Lecous de Clinique Médicale

For related article see page 806

Despite advances in prophylaxis, diagnostic modalities, and therapeutic options, pulmonary embolism (PE) remains a commonly underdiagnosed and lethal entity. PE has been estimated to occur in > 600,000 patients annually in the United States and is reported to cause or contribute to 50,000 to 200,000 deaths.^{1–4} The ongoing magnitude of the problem is illustrated by the results of large

*From the Department of Medicine, University of Wisconsin Hospitals & Clinics, Madison, WI.
Manuscript received January 17, 2001; revision accepted August 16, 2001.

Correspondence to: Kenneth E. Wood, DO, FCCP, Associate Professor of Medicine, Director, Critical Care Medicine, Section of Pulmonary and Critical Care Medicine, K4/930 (9988), University of Wisconsin Hospital & Clinics, 600 Highland Ave, Madison, WI 53792; e-mail: kew@medicine.wisc.edu

autopsy series⁵⁻⁷ in which the incidence of PE directly causing, contributing, or accompanying death in hospitalized patients has remained remarkably constant at about 15% over the last 40 years. Similarly, the antemortem diagnosis of fatal PE has not changed appreciably over the same time interval and remains fixed at approximately 30%.^{8,9} Although two studies of hemodynamically stable PE have reported PE-attributable mortality rates of 1.8% and 4.1%,^{10,11} large contemporary observational studies that have included patients with massive PE¹² or that have focused on hemodynamically significant PE¹³ have reported significantly higher mortality rates. In the International Cooperative Pulmonary Embolism Registry (ICOPER), the overall three month mortality for all PE patients was 17.4%.¹² The in-hospital mortality rate for patients in the Management Strategies and Determinants of Outcome in Acute Pulmonary Embolism Trial (MAPPET)¹³ rose to 31% in those patients presenting with hemodynamic instability. The mortality rate directly ascribed to PE was 45%¹² in the ICOPER and 91%¹³ in the MAPPET. Thus, PE remains common, underdiagnosed, and lethal.

In fatal cases, it has long been recognized that two

thirds of those patients will die within 1 h of presentation^{6,9,14-20} and that anatomically massive PE will only account for one half of those deaths, with the remainder attributed to smaller submassive or recurrent emboli.^{3,6,7,20-31} Although life-threatening PE traditionally has been equated with anatomically massive PE (defined as a > 50% obstruction of the pulmonary vasculature^{3,32-34} or the occlusion of two or more lobar arteries),³⁵ it seems reasonable to propose that the outcome from PE is a function of both the size of the embolus and the underlying cardiopulmonary function. A massive embolus in a patient with adequate cardiopulmonary reserve and a submassive embolus in a patient with prior cardiopulmonary disease (CPD) and poor reserve may manifest similar hemodynamic and clinical outcomes.^{24,36} The length of time from the occurrence of a single embolus or multiple recurrent emboli impacting the cardiovascular system to the accrual of physiologic data is often unknown. When that time period is appreciated, it appears that the magnitude of the cardiovascular abnormalities are diminished with time, probably as a consequence of the intrinsic fibrinolytic system and mechanical fracturing of the embolus. Thus, the length of time to presentation

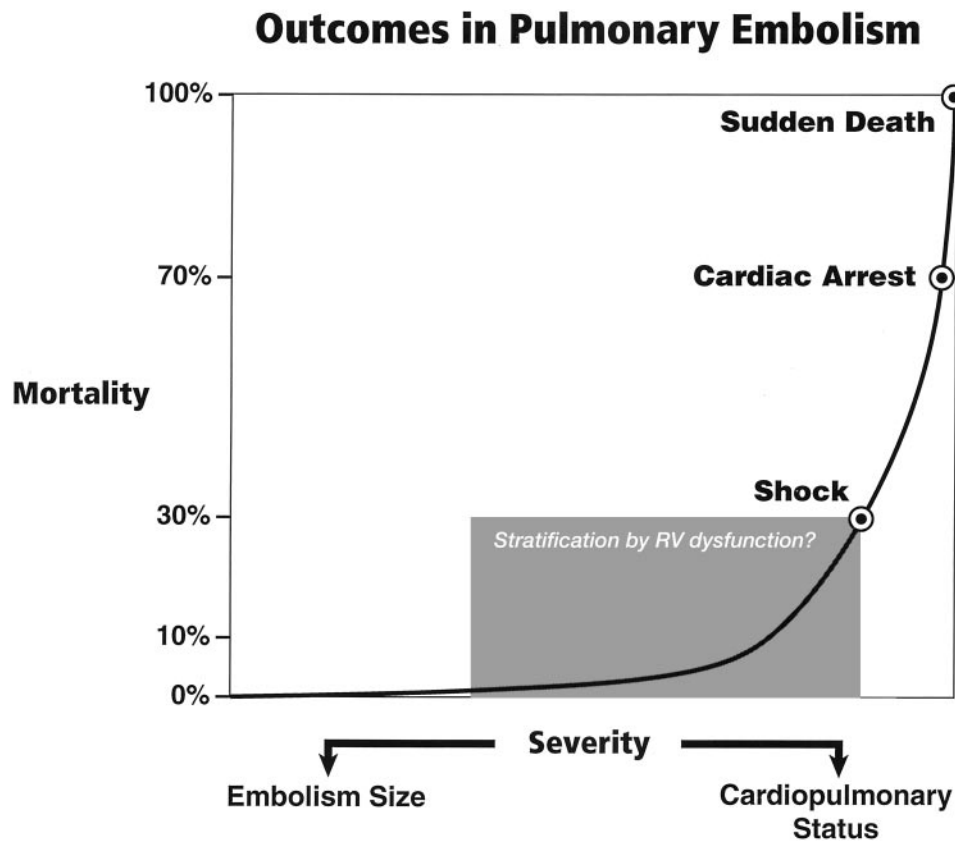


FIGURE 1. The relationship of severity and mortality in patients with MPE.

can add another dimension to the physiologic and outcome characterization.^{32,37,38} In an attempt to integrate embolus size and cardiopulmonary function to reconcile clinical outcome, it has been suggested that the term *major* be used to define any combination of embolus size and cardiopulmonary function that results in a hemodynamically significant event.²² Figure 1 depicts the proposed relationship between mortality and severity as characterized by a combination of embolus size and cardiopulmonary status. Progressive increments in severity are associated with a relatively low constant mortality outcome, provided that therapeutic anticoagulation is achieved. From reported series,^{13,35,39} it is evident that the combination of embolus size and the cardiopulmonary function necessary to produce shock is associated with a mortality rate of approximately 30%. A minimal increase in severity produces cardiac arrest, which has a mortality rate of at least 70% in reported series.^{13,40} However, the exact combination of embolus size and cardiopulmonary status that produces the mortality inflection point remains elusive. The presence of right ventricular (RV) dysfunction in normotensive patients with PE has been proposed to signify this critical point, although this remains controversial as a substantial number of PE patients will have RV dysfunction and low mortality rates.⁴¹ Reconciling the clinical predictors necessary to establish this critical inflection is crucial because it will define the threshold at which patients are deemed to be at sufficient risk with conventional therapy to justify the additional risk and potential benefits of more aggressive and costly therapies. Although it is appealing to define major PE (MPE) as a function of the mortality inflection point characterized by incipient hypotension, a more pragmatic definition is required because the clinical identifiers of the inflection point are unknown at this time. For the purpose of this review, MPE is defined by the clinical spectrum ranging from hypotension to cardiac arrest. Syncope most likely represents an intermediary position, as the failure to regain consciousness inevitably results in cardiac arrest and those patients who recover consciousness have a high incidence of hypotension.⁴²

Hemodynamic instability secondary to RV failure as a function of embolism size and underlying cardiopulmonary status is thought to be a more accurate indicator of the magnitude of PE than the degree of angiographic obstruction.^{33,37,39} The presence of hemodynamic decompensation or shock is associated with an approximate threefold to sevenfold increase in mortality, which is best exemplified in the original observation from the Urokinase Pulmonary Embolism Trial (UPET)³⁵ [mortality, 36% vs 5%, respectively], was confirmed in the series by Alpert et al³⁹

(mortality, 25% vs 5%, respectively), and was contemporarily reconfirmed in the ICOPER study¹² (mortality, 58.3% vs 15.1%, respectively). Interestingly, the mortality rate in the UPET was slightly higher for submassive PE than for massive PE (mortality, 9.8% vs 6.7%, respectively), further illustrating the relationships among embolus size, cardiopulmonary status, and outcome. Data from the largest observational study¹² of PE have reconfirmed systolic arterial hypotension as the most significant prognostic indicator of outcome. Thus, the presence of shock or hemodynamic instability clearly provides an early and readily available discriminator between potential survivors and nonsurvivors. The preceding provides the rationale to devise a physiologic approach to the diagnosis and management of MPE.

As the physiologic response to MPE within the first hour will very likely determine the survival and availability of patients for subsequent studies, survivors of MPE, particularly those who have been entered into clinical trials, represent a selected group. There are no randomized prospective trials designed to study MPE, and it is not likely that any will be undertaken. Hemodynamic instability, impending death, and contraindications to thrombolytic therapy are exclusion criteria in many studies^{10,11,43–48} and undoubtedly preclude a realistic reporting of MPE. Observational case series with variability in operational definitions that rarely integrate hemodynamics, cardiopulmonary status, or embolism size with outcome provide the largest data source for MPE. Cases of anatomically massive PE dominate this literature; however, it is crucial to recognize that this is not equitable to patients with MPE, as only a minority of patients with anatomically massive PE will have hemodynamic instability.^{35,39} Consequently, high-level, evidenced-based recommendations are not available. The purpose of this article is to provide a structured physiologic approach to diagnosis, and to resuscitative and therapeutic strategies as well as a discussion of issues specifically germane to MPE. Similar to the “golden hour” of trauma, myocardial infarction, and stroke, there exists a golden hour of MPE during which a timely approach to diagnosis and therapy potentially can impact outcome.

CIRCULATORY MODEL

The care of the critically ill hemodynamically unstable patient often proceeds along the following two parallel paths: physiologic resuscitation and differential diagnosis investigation. Frequently, the initial physiologic characterization and the subsequent physiologic response to therapy contribute to estab-

lishing the definitive diagnosis and initiating optimal treatment. Accordingly, the utilization of a universally applicable physiologic model of the circulation that allows for the expeditious application of resuscitative and diagnostic strategies is beneficial. This is particularly pertinent to MPE, given the acknowledged difficulty in deciphering the process, the potential for rapid lethality, and controversies in treatment. A fundamental understanding and review of basic hemodynamic principles is imperative to appreciate the pathophysiologic alterations induced by various disease states. Utilizing Poiseuille's law, conventional hemodynamics conceptualize the circulatory system as an open cylindrical conduit with cardiac output (CO) defined as a function of pressure gradients (mean arterial pressure [MAP] – right atrial pressure [RAP]) against resistance (Fig 2). However, recognizing that CO is pulsatile, it is useful to devise a model that includes a hydraulic pump.

Figure 3 illustrates a three-compartment circulatory model that conceptualizes the circulatory system as a hydraulic pump composed of a right heart pump linked in series to a left heart pump. As a consequence of this serial hydraulic alignment, CO cannot exceed venous return (VR) and vice versa. In other words, left heart output cannot exceed right heart output, which allows for the conceptualization of both pumps as a single hydraulic unit. The hydraulic pump is primed with volume from the venous capacitance bed [*ie*, the volume reservoir] and empties into the arterial impedance bed (*ie*, the resistive element). Guyton et al⁴⁹ recognized that the pressure gradient for VR is the ratio of pressure in the venous capacitance bed (PVC) to the RAP

(VR = PVC – RAP), thus establishing the integral role of the right atrium (RA) as a coupler of the venous system and cardiac hydraulic circulation. The graphic solution of this observation is depicted in Figure 3. PVC is a function of venous volume and vascular tone, which must exceed the RAP to maintain VR. The RAP provides not only an assessment of the pressure in the right heart but an indirect gauge of the pressure in the venous capacitance system. Thus, the circulatory system can be defined as a three-compartment model; a capacitance bed that provides volume to a hydraulic pump that generates flow into an impedance bed. Any hemodynamic abnormality can be characterized by disturbances of one or more of these three variables. The surrogates for venous capacitance pressure, hydraulic pump function, and impedance are RAP, CO, and systemic vascular resistance (SVR), respectively. Invasive monitoring is frequently not in place on initial presentation, and, given the controversies surrounding its risks and benefits,⁵⁰ it is prudent to utilize readily available physical examination surrogates to define the model variables. Estimation of the RAP from the internal jugular vein approximates the pressure in the venous capacitance system, and the pulse character and temperature of the extremities approximate impedance (resistance). Warm flushed extremities with a wide pulse pressure indicate low impedance (*ie*, resistance), whereas cool constricted extremities with a narrow thready pulse suggest high impedance (*ie*, resistance). The latter is a consequence of the catecholamine-mediated vasoconstriction that is initiated to create perfusion pressure gradients to redistribute and optimize the low-flow state. In shock patients, flow and resistance are

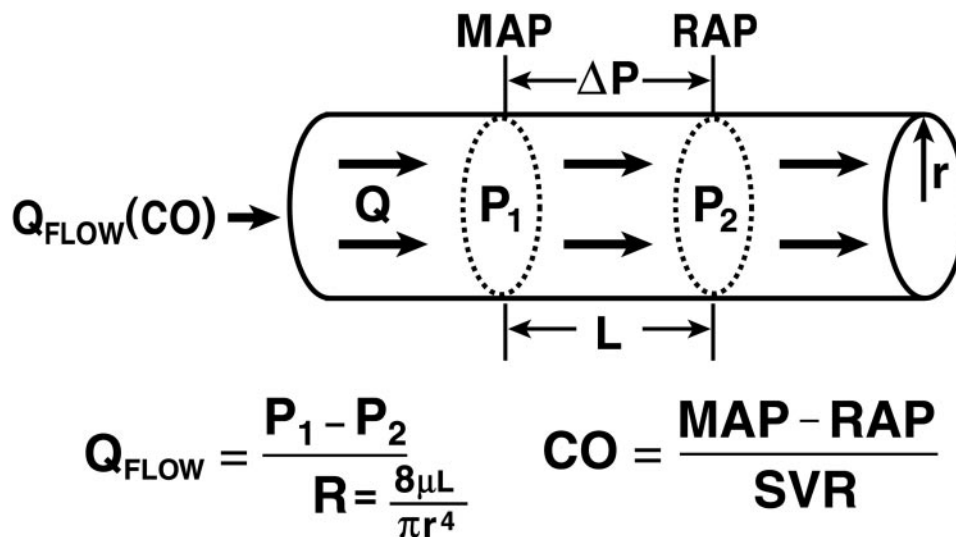


FIGURE 2. Poiseuille's law representing the relationships among flow (Qflow), pressure, and resistance.

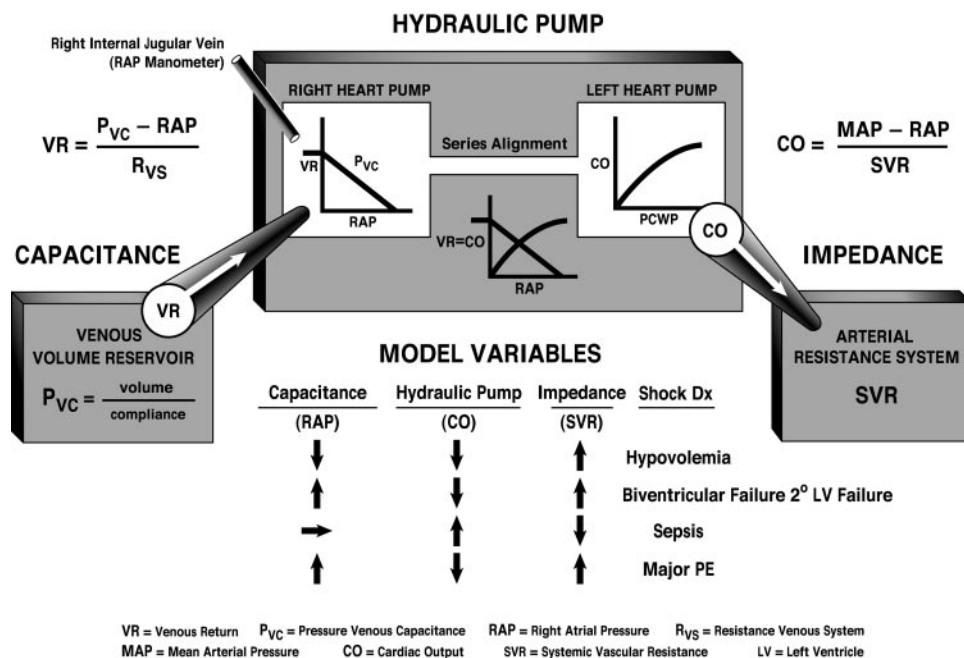


FIGURE 3. Hydraulic model of the circulation.

almost uniformly reciprocal ($Q_{\text{flow}} \times \text{resistance} = \text{pressure}$ or $\text{CO} \times \text{SVR} = \text{BP}$). Therefore, the initial assessment of impedance (*ie*, resistance) allows for the inferential derivation of hydraulic flow (*ie*, CO). Obviously, invasive monitoring will be needed if the physical examination findings cannot be well-characterized. Representative examples are illustrated in Figure 3.

PATHOPHYSIOLOGY

Mechanism of Cardiac Failure

Cardiac failure from MPE results from a combination of the increased wall stress and cardiac ischemia that comprise RV function and impair left ventricular (LV) output. Research from animal models and evidence from clinical investigations clearly demonstrate that the impact of embolic material on the pulmonary vascular outflow tract precipitates an increase in RV impedance. This initiates the vicious pathophysiologic cycle depicted in Figure 4. The degree of increase in RV impedance is predominantly related to the interaction of the mechanical obstruction with the underlying cardiopulmonary status.⁵¹⁻⁵³ Additional factors reported to contribute to increased RV impedance include pulmonary vasoconstriction induced by neural reflexes,⁵⁴ the release of humoral factors⁵⁵ from platelets (*ie*, serotonin and platelet activating factor), plasma (*ie*, thrombin and vasoactive peptides C3a, C5a), tissue

(*ie*, histamine), and systemic arterial hypoxia.⁵⁶ The acute development of this increased RV impedance constitutes a pressure afterload on the RV and has multiple effects on RV and LV function.

Given the reciprocal relationship between RV stroke volume and vascular load, RV stroke volume will diminish with increasing load.⁵⁷ Initially, the compensatory maintenance of CO is achieved by a combination of catecholamine-driven tachycardia and the utilization of the Frank-Starling preload reserve (the latter being responsible for RV dilatation). This increase in RV cavity pressure and radius serves to significantly increase RV wall stress (wall stress = pressure \times radius). This is the primary determinant of RV oxygen uptake, thus creating the potential for RV ischemia. With increasing RV load and wall stress, RV systolic function becomes depressed and CO begins to decrease. Interestingly, systemic BP may be adequately maintained by systemic vasoconstriction at this point.⁵⁸ From the point of initial CO depression, it has been reported⁵⁹ that increases in load sufficient to further decrease CO by 20% will result in a disproportionate increase in end-systolic volume compared to end-diastolic volume. Afterload mismatch has been used to describe the phenomenon of RV pressure work exceeding RV volume work in this setting.⁶⁰ As a consequence of this mismatch, LV preload will decrease, given the ventricular alignment in series. LV preload is additionally impaired by decreased LV distensibility as a

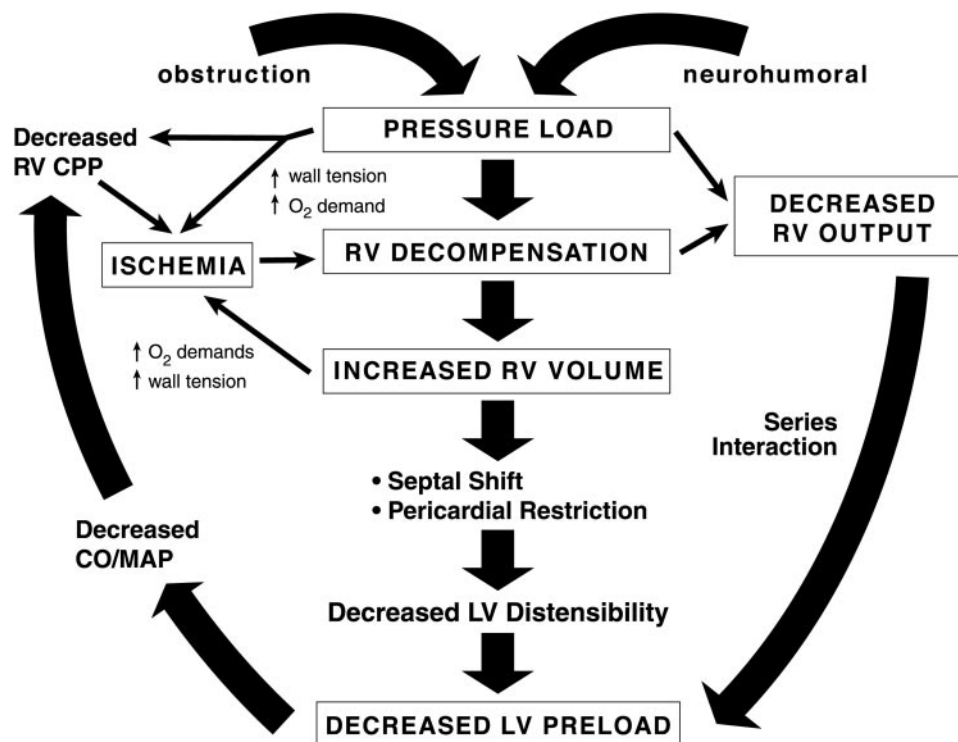


FIGURE 4. Pathophysiologic cycle of MPE.

consequence of a leftward shift of the interventricular septum and of pericardial restraint, both of which are related to the degree of RV dilatation.^{61–63} It also has been suggested that MPE may impair LV function independently of preload mechanisms.⁶⁴ In the presence of declining LV forward flow, MAP can be maintained only by catecholamine-induced vasoconstriction. A further decrease in LV flow results in systemic hypotension. RV coronary perfusion pressure (CPP) depends on the gradient between the MAP and the RV subendocardial pressure. Decreases in MAP associated with increases in RV end-diastolic pressure (RVEDP) impair the subendocardial perfusion and oxygen supply. Elevated right-sided pressures can further impair coronary perfusion and LV distensibility by increasing coronary venous pressure.⁶⁵ Increased oxygen demands associated with elevated wall stress coupled with decreased oxygen supply have been shown to precipitate RV ischemia, which is thought to be the cause of RV failure.⁶⁶ Clinical evidence of RV infarction as a consequence of the preceding condition has been demonstrated in patients with and without obstructive coronary disease.^{67–69} A reversal of PE-induced RV ischemia and RV failure can be accomplished by the infusion of vasoconstrictors to raise aortic pressure and to increase the coronary perfusion gradient.^{66,70}

Translation of the pathophysiology of MPE into the previously discussed three-compartment hydraulic model of the circulation is shown in Figure 5. Catecholamine-induced vasoconstriction increases the PVC to maintain a pressure gradient for VR in response to the PE-induced RAP elevation. The impairment of RV hydraulic pump function compromises LV hydraulic output, which is manifested as systemic arterial hypotension. Thus, the model variables would reveal an increased RAP, a decreased CO, and an increased SVR. The clinical correlates would be jugular venous distention, a thready pulse, and cool extremities, respectively.

Gas Exchange

Gas-exchange abnormalities in patients with PE are complex and are related to the size and character of the embolic material, the extent of the occlusion, the underlying cardiopulmonary status and the length of time since embolization.⁷¹ Hypoxemia has been attributed to an increase in alveolar dead space,⁷² right-to-left shunting,^{73,74} ventilation/perfusion (\dot{V}/\dot{Q})^{75,76} inequality, and a low mixed venous O_2 level.⁷¹ The two latter mechanisms are proposed to account for the majority of observed hypoxia and hypocarbia before and after treatment.⁷⁷ Low \dot{V}/\dot{Q} ratios reportedly can develop as a consequence of

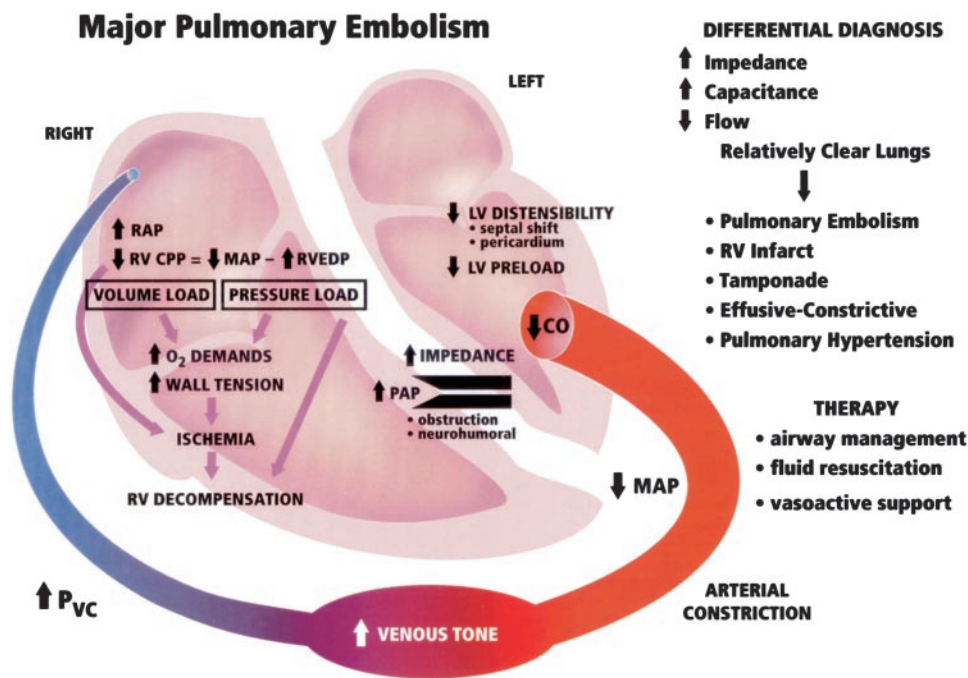


FIGURE 5. Hydraulic model of MPE.

the redistribution of blood flow away from the embolized area, resulting in overperfusion of the unembolized lung regions⁷⁸ and atelectasis that initially develops distal to the embolic obstruction yet persists after early embolism dissolution and resultant reperfusion.⁷³ Atelectasis may arise from a loss of surfactant and alveolar hemorrhage⁷⁹ or an “air shift” phenomenon as regional hypocarbia related to regional hypoperfusion induces bronchoconstriction,⁸⁰ both of which are compounded by humoral mediators released from platelet-laden emboli.⁸¹ Postembolic pulmonary edema and flow through a patent foramen ovale that is induced by high RAP also have been implicated.⁸² In patients with massive PEs and circulatory failure, it has been reported that the augmentation of a low CO with medical therapy can decrease the PaO₂. This was attributed to an increase in physiologic shunting because of increased flow through areas with low \dot{V}/\dot{Q} ratios and may explain some of the PaO₂ variability in reported series.⁸³

Role of Severity of Pulmonary Vascular Obstruction

Without Prior CPD: It is particularly instructive to review the clinical manifestations of PE in patients without prior CPD because it allows for the examination of the pure effects of the disease and the specific compensatory responses. In this population, the clinical and physiologic manifestations of the disease are directly related to embolism size.^{37,84,85}

Good correlation has been observed between the degree of angiographic obstruction and mean pulmonary artery pressure (mPAP), RAP, PaO₂ and pulse.^{37,84,85} In the absence of angiographic quantification, it has been suggested that a pulmonary vascular resistance (PVR) of $> 500 \text{ dyne} \cdot \text{s} \cdot \text{cm}^{-5}$ is associated with $> 50\%$ obstruction.⁸⁶ Depression of the PaO₂ is frequent, occurs with as little as 13% obstruction, usually is the only clinical manifestation when the obstruction is $\leq 25\%$, and roughly quantitates the extent of the embolus.⁸⁵ Pulmonary artery (PA) hypertension (normal mPAP, 20 mm Hg) is the next most frequent finding and begins to manifest only when ≥ 25 to 30% of the pulmonary vascular bed is obstructed.⁸⁵ This represents an increase in mPAP in excess of that observed in similarly described degrees of nonembolic experimental obstruction, further implicating the previously described⁸⁷ neurohumoral/hypoxia mechanisms as contributing culprits. Despite massive embolic obstruction of $\geq 50\%$, patients without prior CPD are unable to generate an mPAP of ≥ 40 mm Hg, which appears to be the maximal pressure that a healthy ventricle can generate.^{84,85} Either a single massive embolus or the cumulative incremental effects of multiple recurrent emboli totaling $\geq 75\%$ obstruction would necessitate an mPAP of ≥ 40 mm Hg and, consequently, would precipitate RV failure.⁸⁸ Accordingly, mPAP values of ≥ 40 mm Hg represent either the baseline underlying CPD or the cumula-

tive effects of multiple embolic events over a greater period of time, allowing for RV hypertrophy. Although correlated with the degree of anatomic obstruction, mPAP was not a reliable predictor of cardiac impairment. At high levels of mPAP (*ie*, 30 to 40 mm Hg), elevations or depressions in CO were observed.^{37,85} This suggests that the range of RV failure is narrow with individual patient variation and that an mPAP of 30 to 40 mm Hg should be considered to represent severe pulmonary hypertension in patients without prior CPD.^{37,85} The relationship between PVR and the degree of anatomic obstruction is hyperbolic and not linear. A dramatic increase in PVR occurs when obstruction exceeds 60%.⁸⁹ Insofar as pressure = flow \times resistance, it should be recognized that mPAP can be less than expected in the presence of massive obstruction if the RV is failing and cannot generate forward flow.³²

Increased RAP in the setting of PE almost always indicates severe pulmonary vascular obstruction in the absence of other CPD. RAP elevation is directly related to mPAP but occurs less frequently and is unusual until mPAP is \geq 30 mm Hg and obstruction exceeds 35 to 40%. RAP is consistently elevated with an mPAP of \geq 30 mm Hg, and it has been reported that a RAP of \geq 10 mm Hg is generated by an obstruction \geq 50%, whereas obstruction \leq 25% is associated with a RAP of \leq 10 mm Hg.^{84,85} However, it should be recognized that substantial obstruction (*ie*, \geq 30%) can occur without significant elevations in RAP in this population.⁸⁵ Elevations in RAP reflect the compensatory use of the Frank-Starling preload mechanism. Thus, RAP can be elevated without a decrease in CO in patients with PE, but, as a corollary, a decrease in CO without an increase in RAP should suggest an alternative non-PE diagnosis. Significant elevations in RAP indicate severe RV outflow obstruction providing a reliable index of the degree of encroachment on RV reserve. In patients without prior CPD, CO is characteristically normal or elevated despite substantial anatomic obstruction.⁸⁵ A hypoxically mediated sympathetic response that augments inotropic/chronotropic responses and venoconstriction is reported to be the responsible mechanism.^{90,91} The latter results in the creation of a more favorable pressure gradient for VR, resulting in an augmented Frank-Starling preload response. This is consistent with the observation that CO is initially maintained by increased stroke volume rather than increased heart rate.⁸⁵ A decrease in CO is unusual without at least a 50% obstruction.⁸⁵ The inadequacy of these mechanisms results in cardiac failure that is characterized by RV dilatation and by increased mPAP that is associated with an increased RAP and a predominantly chronotropic response. Insofar as BP is the product of CO

and SVR (*ie*, BP = CO \times SVR), it is likely that hypotension will ensue when systemic vasoconstriction is inadequate to generate pressure in response to decreasing flow. Thus, it appears that there exists a hierarchic series of compensatory cardiovascular responses related to the magnitude of the embolic event, with hemodynamic instability defining exhaustion and the failure of the available compensatory measures.

With Prior CPD: In contrast to patients without prior CPD, patients with prior CPD characteristically manifest a greater degree of cardiovascular impairment with a lesser degree of pulmonary vascular obstruction.⁹² In the Urokinase Embolic Pulmonary massive PE trial,⁹³ 90% of the patients who presented in shock had prior CPD, and 56% of the patients with prior CPD presented in shock, compared to 2% of patients without CPD. Massive obstruction of \geq 50% is uncommonly reported in this population, which suggests that patients with prior CPD who sustain such a massive embolic event often do not survive to be studied or entered into clinical trials. In patients with prior CPD, it has been shown that the level of mPAP is disproportionate to the degree of angiographic obstruction when compared to patients without prior CPD. In a group of patients with prior CPD and a mean angiographic obstruction of only 23%, significant elevations in mPAP were reported. The increased mPAP directly correlated with pulmonary capillary wedge pressure (PCWP),⁹² which suggests that increased mPAP in this population is predominately related to the critical opening pressure for pulmonary flow rather than to incremental resistance in the pulmonary vasculature.⁹⁴ This degree of obstruction is below the threshold to elicit increased mPAP in patients without prior CPD. In the group with prior CPD, the average mPAP was 40 mm Hg, which was the maximum seen in patients without prior CPD.⁹² With prior CPD, the predictive value of the PaO₂ and RAP to define the extent of the vascular obstruction was lost. In contrast to patients without prior CPD, RAP was shown to be an unreliable indicator of the severity of the event, limiting its usefulness as the sign of an extensive and life-threatening vascular obstruction.⁹² Despite a lesser degree of obstruction, CO was uniformly below normal and independent of the magnitude of the obstruction and the level of pulmonary hypertension. Therefore, it appears that no consistent relationship exists between the degree of cardiovascular and RV functional impairment and the magnitude of the embolic obstruction in patients with prior CPD. As such, hemodynamic and RV functional status can be misleading as measurements of the effect of the embolic event and clearly illus-

trate that the estimation of the role and severity of PE in this population is predicated on the consideration of the preembolic cardiopulmonary status and the magnitude of the embolic obstruction. Determining the relative contributions of cardiopulmonary status and embolism magnitude to the postembolic hemodynamic presentation is difficult yet intuitively appealing, as such a characterization could have therapeutic and prognostic implications. The ratio of the mPAP to the percentage of angiographic obstruction has been proposed to distinguish between instances in which the PE is the primary determinant of the hemodynamic abnormality vs those instances in which the prior cardiopulmonary status dominates.⁹⁵ In patients with prior CPD, a ratio ≥ 1.0 was consistently found, which suggests a greater pulmonary hypertensive response per unit of vascular obstruction that is consistent with less reserve in the system.⁹⁵

INCIDENCE AND PRESENTATION

It has been estimated that hemodynamically unstable MPE constitutes 10% of all PE presentations, although this percentage may be higher given the aforementioned selection bias issues.²² In the UPET,³⁵ the Urokinase-Streptokinase Embolism Trial (USPET),⁹⁶ and the ICOPER,¹² 9% (14 of 160 patients), 7% (12 of 167 patients), and 4.2% (103 of 2,454 patients) of all patients, respectively, initially presented in shock. In the Prospective Investigation of Pulmonary Embolism Diagnosis (PIOPED), 10% of all patients (38 of 383 patients) presented in circulatory collapse, as defined by the presence of shock or syncope.⁹⁷⁻⁹⁹ In the largest observational series ever performed, with entry criteria requiring acute right heart failure or pulmonary hypertension due to PE, the MAPPET¹³ reported that 59% of patients had hemodynamic instability on presentation (cardiac arrest, 18% [176 of 1,001 patients]; shock requiring vasopressor therapy support, 10% [102 of 1,001 patients]; and arterial hypotension of < 90 mm Hg not requiring vasopressor therapy, 31% [312 of 1,001 patients]). Syncope deserves special mention because, although it is not a presentation that is commonly recognized to be associated with PE, it has been reported in 13% of patients in large clinical trials^{35,96} and in a large case series.⁴² In the series by Thames et al,⁴² syncope was recurrent (35%) and was more prominent in women (82%) and patient presentations from outside the hospital (70%), but was distributed equally among patients with and without CPD. A comparison of PE patients with and without syncope revealed higher incidences of angiographic obstruction of $\geq 50\%$ (82% vs 28%,

respectively), RAP ≥ 8 mm Hg (88% vs 33%, respectively), cardiac index ≤ 2.5 L/min/m² (70% vs 32%, respectively), arterial PO₂ ≤ 60 mm Hg (83% vs 31%, respectively), new incomplete right bundle-branch block (RBBB) or S₁Q₃T₃ pattern (60% vs 12%, respectively), and cardiac arrest (24% vs 1%, respectively) among patients with syncope. Cor pulmonale was found in 94% of patients, and hypotension, which was initially present in 76% of patients, resolved in 38% of patients but required continued vasoactive support in 62%.⁴² Defining the true incidence of cardiac arrest is problematic, as this patient subgroup is infrequently reported. In the series by Miller et al¹⁰⁰ of 68 patients without CPD and anatomically massive PE (*ie*, $\geq 50\%$ obstruction), cardiac arrest occurred in 29% of patients and was more common in the group experiencing persistent shock. In the MAPPET,¹³ which required pulmonary hypertension or right heart failure due to PE, the incidence of cardiac arrest was 18% (176 of 1,001 patients).

Signs and Symptoms

Given the above-reported incidence, the signs and symptoms of MPE are derived from small numbers of patients in the reported series. In the PIOPED,¹⁰¹ when patients were stratified according to their presenting syndromes, the clinical characteristics of patients with circulatory collapse were derived from five patients. The signs and symptoms of MPE in the 40 patients without CPD in both the UPET and the USPET are compiled in Table 1.¹⁰² In the series by Miller and Sutton³² of 23 patients without CPD and with hemodynamically documented cardiac shock from PE, 87% (20 of 23 patients) experienced the sudden onset of dyspnea, 70% (16 of 23 patients) manifested cardiovascular collapse, and 22% (5 of 22

Table 1—Signs and Symptoms of Major PE in Patients Without CPD in UPET and USPET*

Signs and Symptoms	Circulatory Collapse, %	
	Shock (n = 21)	Syncope (n = 19)
Tachycardia ≥ 100 beats/min	86	58
Tachypnea ≥ 20 breaths/min	81	89
Dyspnea	71	89
Apprehension	71	74
Accentuated P ₂	62	79
Rales	48	47
Fever (temperature $\geq 37.5^\circ\text{C}$)	43	21
Pleuritic pain	38	63
Cough	33	42
DVT	19	42
Hemoptysis	10	5

*Table adapted from Stein et al.¹⁰²

patients) developed central chest pain simulating myocardial infarction. In 48% of patients (11 of 23), there were historical signs and symptoms that were suggestive of minor PE in the week preceding the MPE presentation. In the MAPPET,¹³ 70% of patients (696 of 1,001) had an acute onset of symptoms for < 48 h, 96% of patients (958 of 1,001) were dyspneic, and 71% of patients (710 of 1,001) had a pulse rate of ≥ 100 beats/min. Unfortunately, signs and symptoms from the various hemodynamic subgroups in the MAPPET are not available. Prominent physical findings in the group investigated by Miller and Sutton³² included an arterial pulse that was sharp and of small volume, tachycardia, clinical RV failure with an elevated jugular venous pressure, a gallop rhythm at the left sternal edge, and an accentuated second heart sound. RV hypertrophy was never present on palpation. Physical signs were influenced by the duration of the embolism. For those patients evaluated within 24 h, sinus tachycardia and signs of RV failure (*ie*, elevated jugular venous pressure and gallop rhythm) were uniformly present but were less frequently observed in those presenting ≥ 24 h after the initial event. The preceding signs and symptoms were confirmed by cardiac catheterization, and their presence suggests that the time to presentation contributes an additional dimension to the findings at presentation.³² In the PIOPED,⁹⁸ patients without CPD, with the following associations between signs and symptoms, and the more extreme hemodynamics were noted: third heart sound (mPAP, 39 mm Hg; RAP, 12 mm Hg); RV lift (mPAP, 28 mm Hg; RAP, 8 mm Hg); palpitations (mPAP, 27 mm Hg; RAP, 6 mm Hg); and diaphoresis (mPAP, 26 mm Hg; RAP, 8 mm Hg). In the USPET,¹⁰³ the following were more common in PE shock patients: syncope; cyanosis; diaphoresis; pulse rate ≥ 120 beats/min; respiratory rate > 30 breaths/min; and hepatomegaly. This suggests that the presenting signs and symptoms of MPE, although similar to general PE presentations, are reflective of a more extreme and exaggerated response to the embolic phenomena. Occasionally, invasive monitoring will be in place at the onset of symptoms, which should complement the following hydraulic characterization from a physical examination: an increase in RAP; an increase in PA pressure (PAP); a decrease in cardiac index; and an increase in SVR. The validity of PCWP measurements in patients with massive PE have been questioned because the pressure can be recorded in a vascular zone that is occluded.¹⁰⁴ Using the criteria of an atrial waveform and a PCWP that is lower than the PA diastolic pressure, the PCWP has been reported as being normal in patients experiencing massive PEs.¹⁰⁵ It has been suggested that the shift

in the interventricular septum can distort the LV pressure-volume relationship, potentially producing a “normal” PCWP in the presence of the expected low LV cavitory volume.¹⁰⁶ Patients with CPD can manifest similar findings but commonly have complex presentations that may be dominated by their underlying disease.

BASIC DIAGNOSTIC FINDINGS

The early generation of a differential diagnosis in hemodynamically unstable patients is usually dependent on elements derived from their medical histories and associated risk factors, physical findings, and the basic but readily available diagnostic studies (*ie*, ECG, chest radiograph [CXR], and arterial blood gas measurement). Definitive studies for PE are rarely available in the first hour of clinical presentation, therefore, recognizing the manifestations of MPE from the preceding is crucial to ensure that MPE is appropriately incorporated into the differential diagnosis. Utilizing the previously described hydraulic model of the circulation, physical findings reflective of MPE physiology in patients without CPD can be defined by a characteristic pattern and by the differential diagnosis shown in Figure 5. Increased RAP that is reflective of elevated right heart and venous capacitance pressures in conjunction with high arterial impedance and low cardiac flow (*ie*, narrow pulse pressure and cool extremities) against the background of relatively clear lungs with impaired gas exchange isolates the hemodynamic lesion to the right heart with a differential diagnosis of PE, RV infarct, pericardial tamponade, effusive-constrictive disease, and decompensated pulmonary hypertension. No risk factors that are specific for MPE have been identified, therefore, it is reasonable to assume that the well-described risk factors for PE, which are reviewed elsewhere,¹⁰⁷ are applicable.

ECG

Since the initial description in 1935 by McGinn and White¹⁰⁸ of the S₁Q₃T₃ complex in seven patients with PE-induced cor pulmonale, a myriad of ECG manifestations have been reported. Several points from large series regarding ECG findings for PE, in general, warrant emphasis. First, a normal ECG is unusual and was reported in only 14% of UPET patients without CPD¹⁰⁹ (massive PE, 6%; submassive PE, 23%) and 30% of PIOPED patients without CPD.⁹⁷ Second, rhythm disturbances are uncommon. The incidence of atrial fibrillation/flutter is reported as being between 0% and 5%,^{97,109,110} and first-degree, second-degree, or third-degree heart blocks or ventricular dysrhythmias are

rare.^{97,109} Third, the most common ECG findings are abnormalities in the ST segment and T wave. In the UPET,¹⁰⁹ nonspecific T changes occurred in 42% of patients and ST-segment elevation or depression occurred in 42% of patients. In the PIOPED,⁹⁷ 49% of patients had nonspecific ST-segment or T-wave abnormalities. In other series,^{111–115} an isolated T-wave inversion occurring in 46 to 68% of patients was observed to be the most common abnormality. Fourth, the ECG abnormalities associated with PE are usually transient, with abnormalities of depolarization normalizing earlier than repolarization.^{97,109} The rapidity and extent of the resolution of the T-wave inversions have been shown to correlate with the therapeutic efficacy of thrombolytic agents.^{113,114}

The ECG manifestations of PE are thought to be related to the severity of the embolism when it is defined by lung scans or pulmonary angiograms.^{109,113,114,116,117} In the UPET,¹⁰⁹ patients with ST-segment abnormalities, T-wave inversion, pseudoinfarct pattern, right axis, incomplete RBBB, and an S₁Q₃T₃ pattern had larger perfusion defects. An S₁S₂S₃ pattern, and all of the preceding patterns except the S₁Q₃T₃ pattern, were associated with a higher PAP and RVEDP. RV stroke work and PVR were not related to ECG abnormalities.¹⁰⁹ The ECG correlate of acute cor pulmonale (*ie*, right axis deviation, complete or incomplete RBBB, S₁Q₃T₃, and P pulmonale) occurred in 32% of patients with massive PEs in the UPET.¹⁰⁹ In the series by Miller and Sutton³² of 23 patients without CPD and with massive PEs and shock, 78% showed abnormalities of conduction or repolarization of the RV. RBBB was present in 22% of patients, S₁Q₃T₃ pattern and T-wave inversion in V₁ through V₄ was present in 27% of patients, an rSR pattern in V₁ was present in 17% of patients, an S₁Q₃T₃ pattern and an inverted T wave in the avF was present in 17% of patients, and a normal ECG was present in 17% of patients. In two studies, the pattern of anterior T-wave inversions in the precordial leads has been shown to represent the ECG finding that best correlates with the severity of the PE.^{113,114} This occurred in 85% of patients with massive PEs vs 19% of those with nonmassive PEs, and, when present, 90% of patients had an obstruction score of $\geq 50\%$ and 81% had an mPAP of ≥ 30 mm Hg. The early appearance of the pattern is an even stronger predictor of severity. When the pattern was present on day 1, the obstruction score was 69% compared to 52% when it developed after day 1. Pattern reversibility correlated with physiologic resolution, particularly in patients receiving thrombolytic therapy. In this group, the early normalization of the T-wave inversion pattern was reflective of significant physiologic improvement, which was evidenced by a

postlysis mean obstruction score of $< 20\%$ and a mean mPAP of < 20 mm Hg, with average changes of 57% and 18 mm Hg, respectively.¹¹⁴

The physiologic basis for the ECG changes associated with PE remain undefined. In a series of experimental and clinical observations in 1938, Love et al¹¹⁸ concluded that RV dilatation was responsible as they observed ECG changes that were similar to those of PE with mechanical obstruction of the PA and noted that visible RV dilatation uniformly preceded the ECG changes. Several observations^{114,119} argue against this phenomenon as the sole cause. The clinically observed lag time between the onset of RV dilatation/pulmonary hypertension and the ECG changes can range from hours to days, there can be a persistence of the ECG changes for days after angiographic and hemodynamic resolution, and echocardiographically documented, PE-induced RV dilatation does not uniformly produce ECG changes.^{114,119}

In view of early reports of PE-induced myocardial infarction in patients with massive PEs and normal coronary arteries,^{64,120–122} it is conceptually appealing to attribute the ECG findings to myocardial ischemia¹²¹ and/or to RV wall stress.¹²³ However, two reports^{113,124} utilizing early myocardial scintigraphy with MIBI and CPK enzyme assessment in patients with anterior T-wave changes have failed to demonstrate perfusion defects or enzyme leaks that are suggestive of ischemia.

CXR

The CXR cannot be used to include or exclude the diagnosis of MPE. Albeit nonspecific, the CXR contributes to the diagnostic assessment of MPE by excluding diseases that mimic PE, by defining abnormalities that warrant further evaluation, and by providing a crude estimate of severity.¹²⁵ A normal CXR in patients with proven PE is unusual and occurred in only 16% and 34%, respectively, of patients in the PIOPED⁹⁷ and UPET¹²⁶ who were free of CPD. An association between PE severity and radiographic findings is supported by examining the relationships among the PAP, the alveolar-arterial oxygen pressure difference (P[A-a]O₂), and the CXR findings in PIOPED patients. The lowest values for both were observed in patients with a normal CXR, whereas higher values were related to parenchymal and vascular findings.¹²⁵ Vascular findings appear to be more indicative of PE severity. In the UPET,¹²⁶ a normal CXR and parenchymal signs occurred with comparable frequency among patients with massive PEs (*ie*, affecting two or more lobar arteries) and submassive PEs. However, vascular signs, particularly focal oligemia and/or distention of the proximal portion of the PA were more common in massive

than submassive PEs (43% vs 28%, respectively).¹²⁶ Similarly, in large case series concerning patients with obstruction of $\geq 50\%$, McDonald et al³⁷ reported oligemia in 44% of patients, and Miller and Sutton³² uniformly found oligemia in patients without CPD and shock. Kerr et al¹²⁷ observed oligemia in all patients, with the angiographically defined area evident in 79% of CXRs and hyperemia secondary to blood flow redistribution defined in 40% of CXRs. Thus, whether alone or in conjunction with other CXR abnormalities, focal oligemia should foster a heightened sense of awareness for PE in the patient with undifferentiated shock.

Arterial Blood Gas Analysis

Despite the impressive list of physiologic abnormalities that are responsible for hypoxemia in patients with PE, several caveats from large series should be recognized regarding the use of blood gas analysis in the diagnostic assessment of PE. First, hypoxemia is not uniform, as a PaO_2 of ≥ 80 mm Hg was seen in 12% of the UPET patients and in 19% of the PIOPED patients.^{128,129} Second, a normal P(A-a)O_2 does not exclude PE^{97,130,131} and occurred in 14% of the PIOPED patients.^{97,130} Among patients who had PaO_2 values (≥ 80 mm Hg) and PaCO_2 values (≥ 35 mm Hg) that were not low and a normal P(A-a)O_2 , 38% of patients without CPD and 14% of patients with CPD had angiographically proven PE in PIOPED.¹²⁸ Given the reported relationship between PE severity and PaO_2 or P(A-a)O_2 ,^{85,130,132} the preceding values most likely reflect the presence of minor PEs. McIntyre and Sasahara⁸⁵ reported a linear relationship between PE severity (as assessed by the degree of angiographic obstruction, mPAP, and cardiac index) and PaO_2 levels in patients without CPD, but no correlation was found in patients with CPD. In PIOPED patients with and without CPD, a close correlation was observed between the P(A-a)O_2 , and the mPAP and the number of mismatched perfusion defects. For example, in patients with a P(A-a)O_2 of ≤ 20 mm Hg, the mPAP was ≤ 20 mm Hg and the number of mismatched vascular perfusion defects was three or less.¹³⁰ Hypocarbica and the accompanying respiratory alkalosis are common in patients with PEs,^{133,134} as even patients with baseline CO_2 retentive lung disease will reduce their PaCO_2 level after experiencing a PE.¹³⁵ In patients with MPE, both respiratory and metabolic acidosis may be present, the former as a consequence of increased physiologic dead space ventilation (VD/VT) and respiratory muscle use, and the latter when related to tissue hypoperfusion with shock.^{136,137}

Contemporarily, the use of VD/VT determinations

and the d-dimer assay is not standard or universally available, as their role is being defined by the evolution of the literature.¹³⁸⁻¹⁴¹ An increase in alveolar VD/VT is an inevitable consequence of PE, which can be quantified by measuring the volume and partial pressure of CO_2 with bag collection or end-tidal CO_2 by capnography.^{142,143} Studies^{141,144,145} that compared VD/VT measurements to PE defined by \dot{V}/\dot{Q} scanning and/or angiograms showed excellent sensitivity ($\geq 90\%$) and specificity ($\geq 85\%$). In a study¹⁴⁶ of critically ill surgery patients that included patients with ARDS who were receiving mechanical ventilation, VD/VT measurements had a sensitivity of 100% and a specificity of 89%. It has been reported that VD/VT measurements correlate with the degree of vascular obstruction and its resolution with thrombolytic therapy.¹⁴⁷ Elevated levels of d-dimer are found in patients with deep venous thrombosis (DVT) and/or PE and in patients with many other clinical conditions in which fibrin cross-links are cleaved by plasmin, which accounts for the low reported specificity. The high sensitivity and corresponding negative predictive values potentially make it an ideal test to exclude the presence of PE.¹³⁸ The standard enzyme-linked immunosorbent assay provides an accurate quantitative measurement but it is expensive and labor intensive. The enzyme-linked immunosorbent assay method utilizes batch analysis, not single-patient analysis that requires 2 to 4 h to perform, which essentially precludes its use in the golden hour of MPE.^{138,148} The semi-quantitative latex assay is faster and less expensive but has a low and unacceptable sensitivity.^{149,150} The new generation of rapid d-dimer assays can provide accurate results within minutes and may soon be incorporated into the standard diagnostic evaluation.¹⁵¹

Utilizing the basic and readily available data, a differential diagnosis is constructed and a clinical suspicion for PE is cultivated.¹⁵² The latter is important because clinical suspicion, when combined with the findings of \dot{V}/\dot{Q} scanning, has been shown to establish the diagnosis or to define the need for further, more definitive diagnostic testing.^{153,154}

DIAGNOSTIC-THERAPEUTIC APPROACH

Shock as a Discriminator

The most consistent operational definition of shock in the PE literature is the presence of hemodynamic instability. With a literature span of 30 years and data predominately derived from case series and subsets of patients from various trials, there is no standard definition. At a minimum, this pragmatic definition requires the presence of hypotension (*ie*, systolic BP ≤ 90 mm Hg) and/or the use of vaso-

pressor therapy. The presence of shock in patients with acute PE, either as a consequence of a massive PE in patients without CPD or as a consequence of a submassive PE in patients with CPD, represents a failure of the available compensatory mechanisms to sustain BP and/or tissue perfusion and is associated with a significant increase in mortality. Shock provides an early, readily available, and reliable discriminator between survivors and nonsurvivors. Tables 2 and 3 illustrate the relationships among shock, embolism size, and outcome that have been reported in large series. Uniformly, the presence of shock is associated with a threefold to sevenfold increase in mortality.^{35,39,100,155-157} Massive PE traditionally has been defined by an angiographic obstruction of $\geq 50\%$ or obstruction of two lobar arteries,^{3,35} conditions that occurred in 56% of patients in the UPET^{35,96} and in 64% of patients in the USPET.⁹⁶ The vast majority of patients with anatomically massive PEs do not present in shock.^{35,39,46,155-158} Meneveau et al¹⁵⁸ reported that only 2 of 66 patients without CPD and with massive PEs required vasopressor therapy and that CO was normal in 97% of patients. It is important to recognize that hemodynamically stable patients who are not in shock but who have experienced massive or submassive PE have similar mortality rates.^{35,39} A massive PE, unless accompanied by shock and hemodynamic instability, does not appear to be associated with an increased mortality rate.^{35,39,46,100,155-158} Several large series^{45,46,158} have reported a 0% mortality rate in patients with massive PEs who were not in shock, and others^{35,39,44,47,100,155-157,159} have reported a 3 to 8% range.

The preceding observations are best exemplified in the series by Alpert et al³⁹ and in the UPET³⁵ in which the mortality rates for patients in shock compared to those not in shock were reported (Alpert et al, 25% vs 5%, respectively; UPET, 36% vs 5%, respectively). In the series by Alpert et al,³⁹ the mortality rate for hemodynamically stable non-shock patients with massive PEs was 6.5% compared to 8.8% for all patients.³⁹ In the UPET,³⁵ the mortality

rate for these patients was 5.1% compared to 8.1% for the entire group. Impressively, the mortality rate for patients experiencing submassive PEs (9.8%) was slightly higher than that for those experiencing massive PEs (6.7%), as all of the patients in shock died.³⁵ The highest mortality rate is reported in hemodynamically unstable shock patients experiencing massive PEs.^{35,39} Utilizing shock as an algorithmic discriminator, a diagnostic-therapeutic approach to the patient with suspected MPE is presented in Figure 6. In the nonshock patient, death within the first hour is unlikely, and the tempo of the evaluation is less urgent than that for the patient in shock. The patient should receive heparin therapy and can be transported for diagnostic assessment. Current diagnostic approaches include \dot{V}/\dot{Q} scanning, pulmonary angiogram, helical CT scanning, MRI, and compression ultrasound, either alone or combined in an algorithmic sequence.¹⁶⁰⁻¹⁶² When perfusion defects are $\geq 30\%$ or when anatomically massive PEs are detected, echocardiographic assessment has been advocated to identify a subpopulation with RV dysfunction. This group is reported to have a higher mortality rate with a greater risk of recurrence and may benefit from thrombolysis, although this treatment is controversial.⁴¹ In contrast, the shock patient is much more likely to die within the first hour, and the tempo of the evaluation must be rapid. Ideally, the diagnostic evaluation should begin in the area where the patient can be optimally resuscitated and stabilized. Duplex venous ultrasound is appealing because it is readily available, has excellent sensitivity and specificity for DVT in symptomatic patients, and a positive finding can exploit the identical treatment for DVT and PE.¹⁶³ Although venogram-detected DVT has been reported in 70 to 90% of PE patients,¹⁶⁴⁻¹⁶⁶ the documentation of DVT by ultrasound occurs in $< 50\%$ of PE patients.^{164,167,168} The absence of DVT by ultrasound does not preclude PE, and the presence of DVT does not confirm PE as the primary culprit, as DVT may be incidental to another life-threatening process. Therefore, ultrasound is of limited utility in the initial evaluation of

Table 2—Relationships Among Shock, Embolism Size, and Outcome*

Study	Shock Patients	Nonshock Patients	Patients With Massive PEs in Shock	Patients With Nonmassive PEs in Shock	Patients With Massive PEs Not in Shock	Patients With Nonmassive PEs Not in Shock
UPET ³⁵ (n = 160)†	9/36	91/6	12/18	4/100	88/5	96/6
Alpert et al ³⁹ (n = 136)‡	21/25	79/5	38/32	11/11	62/7	90/4

*Values given as patients, %/mortality, %.

†Treatment with heparin or urokinase.

‡Treatment with heparin or ligation.

Table 3—Anatomically Massive PE Relationship Between Shock and Outcome

Study/Year	Treatment	Shock, %	Mortality, %	Nonshock, %	Mortality, %
Miller et al ¹⁰⁰ /1977	Heparin, lysis, embolectomy	60	22	40	7
Marini et al ¹⁴⁵ /1988	Urokinase/heparin	0	0	100	0
Verstraete et al ¹⁵⁶ /1988	rt-PA	21	14	79	4
Tilsner ¹⁵⁷ /1991	Urokinase	11	40	89	2
Diehl et al ¹⁵⁵ /1992	rt-PA	33	22	67	3
Sors et al ¹⁴⁶ /1994	rt-PA	17	0	83	0
Meneveau et al ¹⁵⁵ /1998	rt-PA streptokinase	3	0	97	0

shock patients but may later assist in the decision to place an inferior vena cava (IVC) filter or to define independently an indication to anticoagulate.

Echocardiography

Echocardiography (ECHO) is enormously useful in this setting because it is readily available and repeatable, is useful in the recognition and differentiation of PE, and is capable of assessing the severity of the PE and the patient’s response to therapy.^{169–171} In the MAPPET,¹³ ECHO was the most frequent diagnostic procedure that was performed in 74% of patients. Although predominantly employed to characterize the presence and the extent of RV pressure overload, transthoracic ECHO (TTE) or transesophageal ECHO (TEE) may detect emboli in transit or may provide alternative diagnoses, such as aortic dissection, pericardial disease, hypovolemia, myocardial dysfunction/infarction, and valvular insufficiency.^{172,173} The latter two were the

most common alternative diagnoses in a study in which definitive echocardiographic findings excluded PE in 42% of patients who were evaluated for suspected PE.¹⁷⁴ ECHO also may be helpful in identifying PE patients with a patent foramen ovale, which is associated with increased mortality, ischemic stroke, and a complicated course.¹⁷⁵ Echocardiographic findings of PE-induced RV pressure overload include the following: RV dilatation/hypokinesis with an increased RV/LV diameter ratio; paradoxical septal motion; PA dilatation; and tricuspid regurgitation (TR).^{105,169–171,173} In patients without CPD, the presence and extent of the above findings correlate with the degree of pulmonary outflow obstruction.^{105,172,173,176–178} RV dilatation is the most common finding and is reported to occur in 50 to 100% of PE cases.^{172–174,176–180}

It appears that an obstruction of $\geq 30\%$ is required to produce RV dilatation,^{176,181,182} which approximates the previously reported^{85,129} degree of

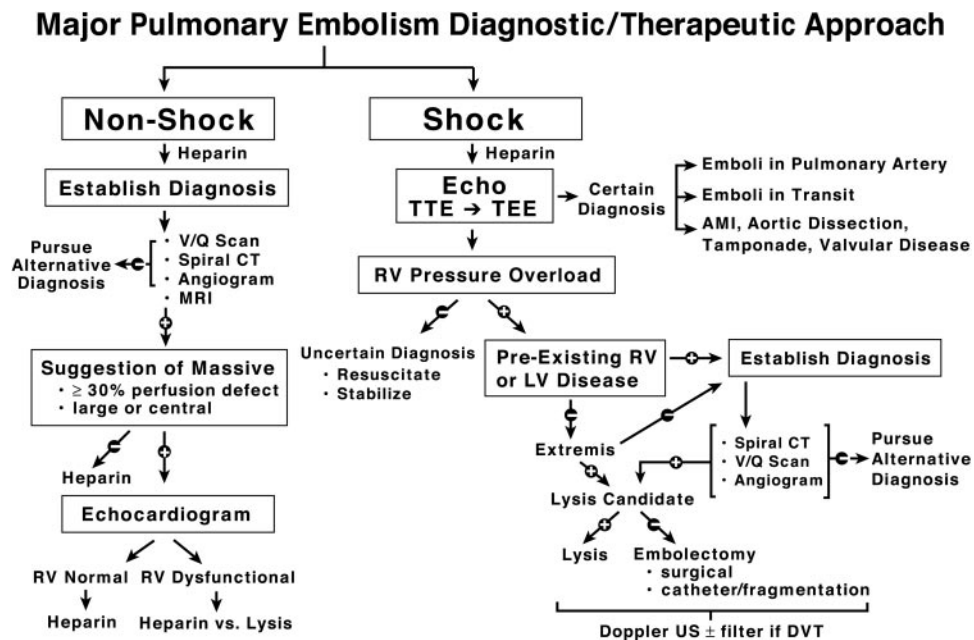


FIGURE 6. Diagnostic-therapeutic approach to MPE. US = ultrasound.

obstruction that is necessary to produce increased PAP. The reported variability and overlap in the percentage of the obstruction-dilatation relationship has led to speculation that the RV pressure response to obstruction may be more important for determining RV dilatation than the absolute degree of obstruction.¹⁸³ Minor PE, which is defined as an obstruction of $\leq 20\%$ or an mPAP of < 20 mm Hg, characteristically does not produce echocardiographic findings of RV pressure overload or RV dilatation.^{179,182} A normal echocardiogram without signs of RV pressure overload effectively eliminates PE as the cause of a shock state.¹⁷⁰ Resuscitation, stabilization, and pursuit of an alternative diagnosis should be undertaken.

The presence of RV dilatation is not specific for PE. However, in the appropriate clinical context, patients without CPD *in extremis* may be considered as candidates for lysis or embolectomy without further confirmatory studies, although this treatment is controversial.^{172,184–187} In patients with preexisting LV pathology, ECHO has not been shown to establish the severity of a superimposed event.¹⁸⁸ In patients with underlying CPD, RV dilatation may be representative of a spectrum of diseases ranging from RV infarct with cardiomyopathy to cor pulmonale with pulmonary hypertension. Several echocardiographic findings have been reported to be useful in differentiating PE from any of the above conditions. Patients with cor pulmonale or recurrent PE characteristically have a hypertrophied RV with a thickness of > 5.0 to 7.0 mm,^{171,179} preservation of the normal inspiratory collapse of the IVC,^{171,176,179} and a minimal septal shift,^{176,179} whereas acute RV failure secondary to RV infarct or acute PE should not be accompanied by RV hypertrophy and is accompanied by a minimal collapse of the IVC with inspiration.^{171,172,176,179} A septal shift is more characteristic of acute PE.^{105,176,177,179} The maximal velocity of the TR jet is directly proportional to the peak systolic pressure gradient between the RV and RA ($\Delta P = 4V^2$) and can reliably be used to estimate PAP.¹⁸⁹ The hypertrophied RV in patients with cor pulmonale or recurrent PE can generate a substantial PAP, occasionally approaching systemic pressures, and is associated with a TR jet of ≥ 3.5 to 3.7 m/s.^{176,177,179,190} RV infarct, cardiomyopathy, and dysplasia have impaired pressure-generating ability and a TR jet of ≤ 2.5 to 2.8 m/s.^{169,171,176,179} Acute PE appears to be intermediate with a TR jet velocity of > 2.5 to 2.8 m/s but < 3.5 to 3.7 m/s,^{169,171,172,176,177,179,191} which is consistent with the previous observations that a healthy ventricle cannot generate an mPAP of ≥ 40 mm Hg.⁸⁵ Reported echocardiographic findings that were specific for PE include a disturbed systolic flow velocity

pattern of RV ejection (sensitivity 48%, specificity 98%)¹⁹² and a distinct regional pattern of RV dysfunction with akinesia of the mid-free wall but normal motion at the apex (sensitivity, 77%; specificity, 94%).¹⁹³ The latter was attributed to a tethering of the RV apex to a contracting hyperdynamic LV, the development of a more spherical shape to equalize wall stress, or localized ischemia.¹⁹³

Unless the occasional clot in transit is directly visualized, TTE provides only indirect evidence of PE. When associated with RV dilatation, the PE is almost uniformly bilateral¹⁹⁴ and, in 50 to 90% of cases, is central or proximal, and can be reliably imaged by TEE.^{194–197} In several large series, patients with suspected PE and documented RV dilatation by initial TTE immediately underwent TEE. Compared to confirmatory reference standards, TEE had a sensitivity range of 80 to 96.7% and a specificity range of 84 to 100%.^{194–197} Comparable sensitivity to spiral CT scanning has been attributed to the ability of TEE to visualize the proximal extending, mobile parts of more distally impacted thrombi.¹⁹⁴ For thrombi beyond the proximal pulmonary arteries, the sensitivity of TEE is reported to be lower (58%).^{195,197} This most likely relates to difficulty visualizing the lobar arteries and the left middle/distal PA given its relationship to the left mainstem bronchus.¹⁹⁶ It has been suggested that utilizing a single-plane probe with rotation enables the visualization of the distal left PA and its lobar branches, which may account for the more balanced prevalence in some studies.^{194,198} Incorporating TEE into the diagnostic algorithm for MPE is appealing because TEE is safe and can be performed at the bedside in critically ill patients^{196,197,199,200} immediately after TTE in patients with RV pressure overload by the same operator with a reasonable likelihood that a definitive diagnosis will be obtained.

Confirmatory Studies

When ECHO cannot be performed or when it documents RV pressure overload but no direct evidence of thrombus, confirmatory studies are necessary. Given the unstable nature of the suspected MPE, choosing the most expeditious approach to achieve a definitive diagnosis is essential. The choice of a confirmatory study may be dictated by hospital culture, expertise, experience, and availability. Traditionally, the \dot{V}/\dot{Q} scan has been considered to be the first-line study, but, unfortunately, it is diagnostic only in a minority of cases. The majority of patients with angiographically documented PE (59%) do not have a high-probability scan.¹⁵⁴ Overall, scan interpretations of normal (15%) or high probability (13%) are rare, as the majority of scans are nondiagnostic

intermediate (39%) and low probability (34%), particularly in patients with underlying CPD.¹⁵⁴ In patients with COPD, normal scans (5%) and high-probability scans (5%) are even less common, and nondiagnostic intermediate scans (60%) predominate.²⁰¹ However, it should be recognized that the positive predictive value of high-probability, intermediate-probability, low-probability, or normal scans is preserved and does not differ between patients with or without CPD or COPD.^{202,203} Stratification according to the presence or absence of CPD has been shown to enhance the predictive value of PE by applying different criteria to both groups.²⁰⁴ In critically ill patients, the sensitivity, specificity, and positive predictive values of high-probability scans are similar to those of non-critically ill patients and are enhanced by concordant clinical assessments.²⁰⁵

Performing ventilation scans in critically ill patients can be difficult.²⁰⁶ Isolated high-probability perfusion scans retain the same sensitivities, specificities, and predictive values even in patients receiving mechanical ventilation.^{205,207} Combining clinical probability with scan probability enhances the predictive value. Combinations of “high-high” or “low-low” are considered to be definitive for the diagnosis or exclusion, respectively, of PE but occur in only a minority of patients.^{154,208} Therefore, with the traditional \dot{V}/\dot{Q} scan approach, the majority of patients subsequently will require angiography as the definitive confirmatory study.²⁰⁹ Angiography is recognized as the “gold standard” confirmatory test but is invasive and expensive, and requires a skilled and experienced staff to perform it. Angiography is not uniformly available²¹⁰ and is associated with multiple complications,^{209,211} particularly in critically ill patients²⁰⁹ and patients with pulmonary hypertension.²¹² In the MAPPET¹³ series of patients with PE related RV dysfunction and hypotension, angiography was performed in only 14% of patients. The established mandatory requirement for angiography prior to aggressive intervention with lysis or embolectomy has been questioned.¹⁵⁴ An embolectomy series²¹³ reported that only 30% of patients had undergone angiography prior to surgery. In patients for whom thrombolysis is a consideration, a noninvasive diagnostic approach has been advocated because of the bleeding associated with angiography.²¹⁴ Thus, given the potential for a delay in diagnosis and associated complications, alternative approaches have been suggested.²¹⁵

Spiral or helical CT scanning is appealing because it is readily available, is noninvasive, and, similar to TTE and TEE, it can detect RV dilation²¹⁶ and can define an alternative diagnosis.^{217,218} Although no study has tested the sensitivity of spiral CT scanning in patients with suspected PEs and shock, it is highly

likely that a filling defect will be demonstrated in this population. When the findings of a spiral CT scan are compared to those of an angiogram for PE in the central arteries (main artery through segmental branches), a pooled analysis of large series reported excellent sensitivity (94%), specificity (94%), and positive predictive value (93%).^{219–224} In cases of acute PE that were considered to be “clinically important” or associated with RV pressure overload, sensitivities and specificities approaching 100% have been reported.^{194,219,222} The overall sensitivity for PE with spiral CT scanning is thought to be approximately 85%.^{225,226} The CT scan sensitivity is somewhat lower in patients who have undergone nondiagnostic \dot{V}/\dot{Q} scans^{219–221,227} but has been useful in confirming the diagnosis in that population.^{221,227–229} The low sensitivity (*ie*, 50 to 60%) in some series^{230,231} has been attributed to the inconsistent ability of spiral CT to detect vessels with subsegmental PE.²³² The frequency of subsegmental PE is reported to be 6%, and interobserver angiographic agreement on the presence of subsegmental PE is only 66%.²³³ The clinical significance of subsegmental PE is uncertain²²⁶ and, therefore, unlikely to precipitate shock. Optimal visualization with spiral CT scanning is achieved by dye injection through a proximal or central vein and by breath-holding.²³⁴ The latter is potentially problematic in the critically ill patient receiving mechanical ventilation and may require a reduction in tidal volume or a brief apneic period in the sedated and/or paralyzed patient. Similar to spiral CT scanning, MRI accurately visualizes the central vessels, provides alternative diagnoses, and reportedly has comparable sensitivity and specificity.^{235–237} The advantages of MRI include eliminating the nephrotoxic contrast load and the potential to undertake MR venography at the same session.^{237,238} However, the contraindications to MRI (*ie*, patient isolation and examination duration) potentially limit its utility in unstable patients. Independent of which confirmatory strategy is employed, the documented presence of PE in the hemodynamically unstable patient defines an indication for aggressive intervention either with thrombolysis or, when thrombolysis is contradicted, surgical or catheter embolectomy.

Resuscitation and Stabilization

Throughout the evaluation period, patients with suspected MPE often require aggressive resuscitation and ongoing stabilization. Marginal native hemodynamic stability is maintained by an intense catecholamine surge. The PE-induced increase in RAP necessitates venoconstriction, which increases PVC to maintain the pressure gradient for VR

(VR = PVC – RAP) [Fig 3]. Similarly, with hypotension related to PE-induced RV dysfunction and increased RVEDP, systemic arterial constriction is necessary to maintain RV CPP (RV CPP = MAP – RVEDP) [Fig 5]. With escalating oxygen requirements or refractory hypoxia, patients with suspected MPE frequently require intubation and mechanical ventilation. Intubation can precipitate cardiovascular collapse for several reasons. First, sedative hypnotics used for intubation can blunt the catecholamine surge on which the patient is dependent for vasoconstriction as well as independently produce vasodilation, both of which impair the above gradients. Second, overzealous initial lung inflation can further decrease VR. Third, the initiation of mechanical ventilation can increase PVR, which can further decompensate the RV. Accordingly, intubation should be undertaken judiciously, weighing the relative benefits and risks of a conscious-awake technique with topical and/or local anesthesia, a rapid-sequence approach with neuromuscular paralysis or fiberoptic intubation. Etomidate is an ideal sedative because it preserves hemodynamic status. Insofar as atelectasis is the most common CXR finding, positive-pressure ventilation has been shown to improve oxygenation in patients with PE.^{73,239} Jet ventilation has been reported to have advantages over conventional ventilation in patients with PE,²⁴⁰ and placing the embolized lung in a dependent position has been shown to improve oxygenation.²⁴¹

Traditionally, volume expansion with 1 to 2 L crystalloid is the initial treatment for hypotension in patients with undifferentiated shock. In patients with anatomically massive PEs and depressed COs who were normotensive and without pressors, Mercat et al²⁴² reported increases in CO with a 500-mL dextran fluid challenge. The increase in CO was universally proportional to the baseline right ventricular end-diastolic volume index. However, in hypotensive patients with severe RV dysfunction that is associated with high RV pressures and volumes causing increased wall stress and/or RV ischemia and a septal shift impairing LV compliance and/or filling, excess fluid administration may compound these problems and precipitate further RV deterioration.^{94,243,244} Therefore, when measured pressures are high or when there is documented severe RV dysfunction, fluids should be used with caution and early consideration should be given to vasopressor therapy. Patients with MPE frequently require vasoactive support, but, unfortunately, there are limited human data in this area. When extrapolated from animal models, it appears that norepinephrine (NE) should be the preferred vasopressor for MPE patients in shock. As early as 1956, it was recognized that the survival of a patient with MPE was dependent on the

maintenance of aortic pressures to provide adequate coronary flow to the stressed RV.²⁴⁵ NE appears to improve RV function through an α -mediated vasoconstrictive effect on the arterial and venous systems. The former generates a higher MAP, which enhances RV CPP (RV CPP = MAP – RVEDP)^{243,246,247} and abolishes RV ischemia,⁶⁶ whereas constriction in the PVC enhances the gradient for VR (VR = PVC – RAP). Additionally, NE possesses β_1 (inotropic) properties that have been shown to provide complementary enhancement of RV function.^{248,249} In patients with massive PEs and circulatory failure, dobutamine increases CO and overall oxygen transport but may alter \dot{V}/\dot{Q} relationships and decrease PaO₂.^{250,251} Dobutamine can cause peripheral vasodilatation through a β_2 effect, which supports the recommendation that dobutamine only be considered in cases of moderate hypotension with appropriate monitoring while NE should be utilized for patients in severe shock.^{70,252} Unloading the RV with pulmonary vasodilators may be useful in patients with incipient or overt RV failure as an adjunct to thrombolysis, in patients with contraindications to thrombolysis or who are awaiting embolectomy. Inhaled prostacyclin and nitric oxide have been reported^{253,254} to increase CO, decrease pulmonary pressures, and improve gas exchange in cases of severe PE.

Heparin

When PE is first suspected, patients should receive heparin at therapeutic doses until PE is excluded, provided that no contraindications to anticoagulation are present.²⁵⁵ Large doses of heparin given as a bolus can precipitate hypotension, which is thought to be related to histamine release as the hemodynamic response can be blocked by histamine 1 and 2 receptor blockers.^{256,257} The efficacy of heparin is attributed to an impairment of clot propagation and the prevention of recurrent PE.²⁵⁸ The risk of recurrent venous thromboembolism is highest in the early stages,^{259,260} and, because recurrent PE is reported to be the most common cause of death in hemodynamically stable patients,^{3,41} it is crucial to rapidly achieve a therapeutic level of anticoagulation. An inability to establish an early therapeutic level for the activated partial thromboplastin time (aPTT) is associated with a higher rate of recurrence^{261,262} and impairs the efficacy of anticoagulation therapy with warfarin.²⁶³ A weight-based heparin nomogram has been shown²⁶⁴ to achieve a therapeutic aPTT more rapidly and to more effectively prevent the recurrence of venous thromboembolism. Although it has been demonstrated that a course of heparin therapy of 4 to 5 days, with warfarin initiated on day 1, is as

effective as the traditional course of heparin therapy of 9 to 10 days,^{265,266} this has not been studied in patients with MPE. For this population, it is recommended that heparin therapy be given for 7 to 10 days and that the initiation of warfarin therapy be delayed until the aPTT is at a therapeutic level for 3 days.²⁶⁷ Patients with massive PEs reportedly have higher heparin dose requirements, and substantial amounts of heparin may be needed to ensure that therapeutic anticoagulation is rapidly achieved and sustained.²⁶⁸ When large doses of heparin are required (ie, $\geq 40,000$ U/d), the optimal heparin dose can be determined by antifactor Xa heparin levels.²⁶⁹ Although low-molecular-weight heparin has been shown to be safe and effective in treating patients experiencing submassive PEs with proximal DVT,^{10,11} its use in patients experiencing massive PEs or MPEs remains unstudied.²⁷⁰ It has been proposed that undergoing anticoagulation therapy with heparin will prevent the accretion of new fibrin on the thrombus, thereby facilitating lysis by thrombolytic agents and reducing the risk of re-extension after thrombolysis.²⁷¹ The greater the angiographic and scintigraphic resolution observed with urokinase (UK) therapy compared to heparin therapy on day 1 in the UPET has been ascribed to a synergism between the UK and the heparin administered during the diagnostic workup prior to randomization.⁴⁵

Thrombolytic Therapy

Thrombolytic therapy in patients experiencing PEs has been extensively reviewed and will be discussed only briefly.^{272,273} Although no definitive mortality data exist, thrombolytic therapy is uniformly acknowledged as the treatment of choice in hemodynamically unstable patients with PE.^{272–274} This should be interpreted similarly for patients without CPD and massive PEs or in patients with submassive PEs and CPD who are manifesting shock or cardiovascular collapse.²⁶⁷

In the PIOPED, thrombolytic therapy was considered to be the standard of care for patients with “shock or major disability.” The investigators considered it “unethical” to treat this group with heparin alone.⁴⁸ Several points regarding thrombolytic therapy and MPE should be stressed. First, when assessed by angiography, perfusion scans, hemodynamic measurements, or ECHO, thrombolytic therapy has been shown to produce more rapid (ie, 2 to 24 h) clot lysis when compared to heparin therapy in all trials^{16,35,41,47,159,275} except two.^{45,48} No trial has reported any difference in the degree of embolic resolution after days 5 to 7. Given the hyperbolic relationship between PVR and vascular obstruction, slight decreases in obstruction (to $\leq 60\%$), as would

be expected with thrombolysis, can significantly reduce PVR and alleviate RV stress.⁸⁹ However appealing the rapid resolution of embolic obstruction may be, only one trial⁶⁹ has demonstrated a mortality outcome benefit. This small trial of only eight patients should be viewed with caution. All four patients randomized to thrombolytics were treated within 4 h of presentation, whereas those patients randomized to heparin therapy had previously failed to respond to it and had experienced recurrent PEs with severe respiratory failure. Second, there does not appear to be any difference in the effectiveness of thrombolytic agents, provided that they are given in equivalent doses over the same time frame.^{158,276} Third, bolus therapy with recombinant tissue plasminogen activator (rt-PA) [0.6 mg/kg/15 min] is equivalent to the traditional 100 mg/2 h.^{46,277} Fourth, IV rt-PA appears to be equivalent to intrapulmonary rt-PA.¹⁵⁶ Fifth, bleeding complications from thrombolytic therapy can be substantial. From pooled analysis, the overall incidence of major hemorrhage associated with PE thrombolysis is reportedly 12% and appears to be similar among thrombolytic agents.²⁷³ Fatal hemorrhaging is thought to occur in 1 to 2% of patients.²⁷⁸ The reported incidence of intracranial hemorrhaging ranges from 1.2 to 2.1%^{272,273,279} and is fatal in at least 50% of cases.²⁷³

Embolectomy

For those patients with contraindications to thrombolytic therapy, “unyielding hypotension” despite maximal medical treatment for ≥ 1 h, or ongoing/intermittent cardiac arrest, treatment with surgical embolectomy should be considered.²⁸⁰ Catheter embolectomy or fragmentation is an option for patients who are not in cardiac arrest.²⁸¹ Availability and expertise are limited, and in the modern era of treatment with medical embolectomy using thrombolytic therapy, surgical embolectomy is rarely performed.²⁸² In MAPPET, only 1% of 594 patients with shock or cardiac arrest underwent the procedure.¹³ For patients in shock or *in extremis*, diagnostic confirmatory studies can delay definitive treatment and contribute to mortality.²⁸³ Several large series^{282–284} have reported that angiograms were performed in only 14 to 67% of patients undergoing embolectomy. Therefore, the operative decision may be based on clinical findings.²⁸⁴ In a compilation series, cardiopulmonary bypass appears to be the preferred operative technique and is associated with improved survival compared to venous inflow occlusion normothermic circulatory arrest (59% vs 48%).²⁸⁵ Proponents of the latter technique stress its greater availability, rapidity, and simplicity with comparable outcomes in selected centers.²⁸⁶ Partial car-

diopulmonary bypass has been advocated for circulatory support in moribund patients requiring angiography.²⁸⁷ Cardiac deterioration with the induction of anesthesia is frequent because of vasodilatation in the presence of a fixed CO.²⁸⁸ The mortality rate in embolectomy series has progressively declined from 57% in the 1960s²⁸⁹ to 26% in contemporary series.²⁸³ However, wide variability is reported (16 to 46%)^{213,282-284,290-294} with higher mortality rates (*ie*, $\geq 40\%$) reported in series with a predominance (*ie*, $\geq 50\%$) of cardiac arrest patients.^{283,284} Cardiac arrest is a recognized predictor of poor outcome, with an approximate mortality rate of 60%.^{213,282-284,286,291,293} Patients who experience intermittent cardiac arrest have a lower mortality rate (42%) than those requiring continuous resuscitation (74%).^{283,284} Mortality rates as low as 3% have been reported in patients who have not experienced cardiac arrest.²⁹⁰ It has also been reported²⁸² that previous thrombolysis does not alter the perioperative risks, and postoperative complications are common in 47% of patients,²⁹² but survivors usually have a functional outcome.²⁹⁵ Catheter embolectomy or fragmentation are alternatives for patients who are not in cardiac arrest. Catheter embolectomy has been shown to reverse systemic hypotension, to decrease PAP, and to improve CO, and it has a mortality rate that is comparable to that for surgical embolectomy in non-arrested patients.^{296,297} Fragmentation is accomplished by catheters²⁹⁸ or rotational devices.²⁹⁹ Innovative pharmacomechanical thrombolysis combining low-dose intraembolic infusion of rt-PA or UK with mechanical fragmentation has been reported to be successful without systemic fibrinogenolysis or bleeding.^{300,301} Indications for placing an IVC filter include the failure of anticoagulation, the inability to anticoagulate, or the inability to tolerate a subsequent embolic event. IVC filter placement for the treatment of a free-floating thrombus in the lumen of the femoral or iliac veins is controversial³⁰² in the patient who is not hemodynamically compromised. IVC filter placement has been shown³⁰³ to reduce the frequency of recurrent PEs in the first 12 days of treatment and should be strongly considered in patients with RV compromise and documented residual DVT.

SPECIAL CONSIDERATIONS

Emboli-in-Transit

Right heart emboli-in-transit have been echocardiographically documented in up to 17% of patients with acute PEs.¹⁷² Given the widespread availability and increasing application of ECHO, it is likely that clinicians will be challenged increasingly to define

their significance and treatment. The European Cooperative Study³⁰⁴ of 119 patients classified emboli-in-transit into two major categories with different morphologies, etiologies, and clinical significance. Type A thrombi are long, thin, extremely mobile, characteristically found in the RA, and originate in the peripheral deep venous system. In a large series³⁰⁵ of patients with massive PEs and cardiovascular instability, right heart emboli were detected in 18% of patients. Eighty-four percent of the emboli were in the RA and measured between 2 and 10 cm in 92% of cases, with prolapse into the RV in 83% of cases. Type-A patients were considered to comprise a high-risk group that was characterized by severe PEs of which one third were fatal within 24 h of the diagnosis. Overall, the rate of early mortality (*ie*, ≤ 8 days) was 44% and was uniformly related to PE. The mortality rate was $\geq 60\%$ in patients who had been treated with anticoagulation therapy alone, 40% in those treated with thrombolysis, and 27% in those who were treated surgically, which led to the conclusion that the presence of type-A thrombi should be considered an absolute surgical emergency.³⁰⁴ Similar findings of association with severe PE, a proclivity to migrate to the PA (precipitating acute deterioration), a high mortality rate (*ie*, $\geq 50\%$) with medical management (*ie*, conservative, anticoagulation, and thrombolytic therapy) compared to surgical management (15%), and recommendations for emergency surgery have been reported in other large series.³⁰⁶

Type-B thrombi are usually smaller, are round or oval-shaped, are less mobile, and arise in the RV. They are commonly associated with known RV thrombogenic abnormalities (*ie*, congestive heart failure, pacemaker electrodes, or cardiac foreign bodies) and resemble an LV thrombus. Although PE is reported to occur in 40% of these patients, it was never fatal and the prognosis was good, independent of treatment type.³⁰⁴ In contrast to the above, Kinney and Wright³⁰⁷ conducted a meta-analysis of 119 case reports in which data were analyzed by multivariate logistic regression analysis in a treatment-received method. All types of thrombi were included in the analysis, and it was found that morphologic characteristics were not related to survival. The overall mortality rate was 31%, and there was no difference in the mortality rate between patients with attached thrombi (28%) and unattached thrombi (39%). Factors predicting survival in patients with right heart thrombi were the presence of PE and the treatment type. The probability for survival in patients with PEs treated with heparin therapy, thrombolytic agents, or surgical embolectomy or who had received no treatment was 0.70, 0.62, 0.62, and 0.19, respectively. The probability for survival in patients without PEs for the same treat-

ment groups was 0.92, 0.89, 0.89, and 0.53, respectively. The authors concluded that the efficacies of all three treatments were similar and suggested that heparin may be the best choice for stable patients.³⁰⁷ In a recent series of hemodynamically unstable patients with PE and right heart thrombus undergoing thrombolysis, continuous echocardiographic surveillance revealed a gradual reduction in echodensity and motility with final disappearance during or shortly after thrombolysis regardless of size or motility. No life-threatening events occurred during this period. Similar observations were reported over several days in stable patients who had been treated with heparin.³⁰⁵ Therefore, it appears that there is more conflict than consensus in the treatment of right heart thrombi and that the approach should be individualized.³⁰⁷

Cardiac Arrest

Cardiac arrest will occur within 1 to 2 h after the onset of clinical presentation in two thirds of fatal PE cases,^{3,15} and acute PE/myocardial infarction reportedly accounts for $\geq 70\%$ of nontraumatic cardiac arrests.³⁰⁸ Therefore, cardiac arrest should be considered to be a risk for all patients with MPEs, and PE should be considered as a diagnosis in all patients experiencing cardiac arrest. In the MAPPET¹³ series of PE associated with RV failure or pulmonary hypertension, 18% of patients presented in cardiac arrest. In arrested patients undergoing resuscitation and stabilization, it is imperative to establish a diagnosis and initiate definitive therapy rapidly. TEE has been reported to be of diagnostic utility when performed in patients in cardiac arrest.^{40,199,200} In a series of 48 arrested patients (13% of whom had PEs),¹⁹⁹ TEE was performed without complications within 16 min of the arrest. The TEE diagnosis was confirmed in 27 of 31 patients when compared to a definite diagnosis from a reference standard for sensitivity, specificity, and positive predictive values of 93%, 50%, and 87%, respectively. In 31% of cases, major decisions were based on TEE findings.¹⁹⁹ In cases of TEE performed during asystole, a paradoxical bulging of the interventricular septum may remain a useful sign because the septum normally occupies a central position in the unloaded nonbeating heart.^{172,309} In one series⁴⁰ of patients in cardiac arrest who were studied with TEE, the incidence of PE was 25% and occurred in 56% of patients with pulseless electrical activity (PEA) and in 64% of patients with RV enlargement without LV enlargement. PE was found only in patients with PEA and RV dilatation. Cardiac arrest due to PE is almost uniformly due to PEA, usually follows shock but may occur spontaneously, and is at least momentarily

reversible in one third of cases. When the PEA-induced arrest is temporarily reversible, the heart rate is frequently normal or high with narrow QRS complexes.³¹⁰ The therapy for suspected PE in patients who are in cardiac arrest consists of cardiopulmonary resuscitation (CPR), which can mechanically fracture the embolus, and thrombolysis or embolectomy. The limited amount of outcome data concerning thrombolysis in this setting is primarily derived from the summary of case reports and small case series by Bottiger et al³¹¹ of the German experience in which thrombolysis reportedly stabilized 77% of patients, with a survival rate of 67%. Thrombolysis was commonly administered as a bolus (1.0 to 3.0×10^6 U UK, or 25,000 to 750,000 U streptokinase, or 10 to 50 mg rt-PA) after conventional CPR had been performed unsuccessfully (for ≥ 90 min in some cases) and occasionally was followed by a lytic infusion.^{311–313} Similar to the reports of thrombolysis in patients who had undergone CPR for myocardial infarctions,^{314–316} there was no increased rate of significant hemorrhagic complications. Patients who had been treated with infusions following arrest and postsurgery patients were at the greatest risk for bleeding.³⁰⁸ Continuing CPR is advocated to allow for thrombolytic activity or to prepare for embolectomy if treatment of the patient is to be pursued aggressively. Experimental data suggest that thrombolysis during CPR may improve cerebral microcirculatory reperfusion by decreasing viscosity and increasing flow.³⁰⁸ The survival rate for patients in the MAPPET presenting with cardiac arrest was 35%,¹³ which is double the reported 14% survival rate for patients who have undergone CPR³¹⁷ and suggests that these patients should be aggressively treated.

Isolated RV Dysfunction

RV dysfunction has long been recognized as a marker for poor outcome in patients with PE, especially in those with hemodynamic instability.^{39,92} RV dysfunction in hemodynamically stable patients has been identified as a predictor of worse outcome in most^{12,41,180,181,190,318,319} but not all studies¹⁸³ and appears to be related to the presence of recurrent PEs.^{41,181,319} Recommendations supporting thrombolysis for hemodynamically stable patients with RV dysfunction justifies their inclusion into the MPE category.³²⁰ Insofar as approximately $\geq 50\%$ of all patients with acute PEs have signs of RV dysfunction, there appears to be a subset of patients within this population with a mortality rate exceeding that for patients with normal RV function but substantially less than that for shock patients.^{12,318,319} It has been reported that 10% of hemodynamically stable patients with RV dysfunction will deteriorate into

shock with a 50% mortality rate attributed to those with recurrent PEs. Multivariate analysis revealed that advanced age, recent trauma or orthopedic treatment, and dizziness or a lower systolic BP on presentation were associated clinical variables.³¹⁹ Thrombolysis has been proposed to be of benefit in this group based on observations from two series,^{41,318} although other studies have reported a worse outcome.³²¹ In the MAPPET,³¹⁸ hemodynamically stable patients with RV dysfunction who were treated with thrombolysis compared to those treated with heparin had a lower mortality rate (4.7% vs 11.1%, respectively), a reduced rate of recurrent PE (7.7% vs 18.7%, respectively), and an increased frequency of major bleeding (21.9% vs 7.8%, respectively). This observational study³¹⁸ should be interpreted with caution because the heparin group was older with a higher incidence of congestive heart failure and chronic pulmonary disease. A recent retrospective study³²¹ of 128 consecutive hemodynamically stable patients with massive PEs and RV dysfunction compared treatment with thrombolysis vs treatment with heparin. Thrombolysis was associated with a significantly higher mortality (6.25% vs 0%, respectively), severe bleeding (9.4% vs 0%, respectively), and intracranial bleeding (4.7% vs 0%, respectively). Given that the vast majority of patients with hemodynamically stable PE and RV dysfunction survive,^{41,319} it is imperative to more precisely define the subset of patients with RV dysfunction who will benefit from thrombolysis, given the substantial cost and risk of bleeding associated with it. Recurrent PE against the background of RV dysfunction appears to be the mechanism for the worse outcome, and perhaps identification of patients with substantial residual DVT will be a discriminator. Unfortunately, randomized trials of thrombolytics have not been shown to significantly decrease the incidence of objectively confirmed recurrent PEs.^{35,47,272} Given the substantial cost and the risk of bleeding, the use of thrombolytic therapy in hemodynamically stable patients with RV dysfunction remains controversial.

CONCLUSION

MPE is dominated by the pathophysiology of the disease, which often defines outcome in the first golden hour. Similar to the golden hour of trauma or myocardial infarction, MPE demands expediency. A pathophysiologic approach to recognition, resuscitation, and treatment provides the greatest opportunity to optimally impact on this lethal disease.

ACKNOWLEDGMENT: The author gives sincere appreciation and gratitude to Doug Coursin, MD, for his review of the manuscript, and to Julie Wardwell for its preparation.

REFERENCES

- 1 Anderson FA, Wheeler HB, Goldberg RJ. A population-based perspective of the hospital incidence and case fatality rates of deep venous thrombosis and pulmonary embolism: the Worcester DVT Study. *Arch Intern Med* 1991; 151: 933-938
- 2 Lilienfeld DE, Chan E, Ehland J, et al. Mortality from pulmonary embolism in the United States: 1962 to 1984. *Chest* 1990; 98:1067-1072
- 3 Dalen JE, Alpert JS. Natural history of pulmonary embolism. *Prog Cardiovasc Dis* 1975; 17:257-270
- 4 Clagett GP, Anderson FA Jr, Heit J, et al. Prevention of venous thromboembolism. *Chest* 1995; 108(suppl):312S-334S
- 5 Nordstrom M, Lindblad B. Autopsy-verified venous thromboembolism within a defined urban population: the city of Malmo, Sweden. *APMIS* 1998; 106:378-384
- 6 Coon WW, Collier FA. Clinicopathologic correlation in thromboembolism. *Surg Gynecol Obstet* 1959; 109:259-269
- 7 Morrell MT, Dunnill MS. The post-mortem incidence of pulmonary embolism in a hospital population. *Br J Surg* 1968; 55:347-352
- 8 Goldhaber SZ, Hennekens CH, Evans DA, et al. Factors associated with correct antemortem diagnosis of major pulmonary embolism. *Am J Med* 1982; 73:822-826
- 9 Stein PD, Henry JW. Prevalence of acute pulmonary embolism among patients in a general hospital and at autopsy. *Chest* 1995; 108:978-981
- 10 Simonneau G, Sors H, Charbonnier B, et al. A comparison of low-molecular-weight heparin with unfractionated heparin for acute pulmonary embolism: the THESEE Study Group; Tinzaparine ou Heparine Standard—Evaluations dans l'Embolie Pulmonaire. *N Engl J Med* 1997; 337:663-669
- 11 The Columbus Investigators. Low-molecular-weight heparin in the treatment of patients with venous thromboembolism. *N Engl J Med* 1997; 337:657-662
- 12 Goldhaber SZ, Visani L, De Rosa M. Acute pulmonary embolism: clinical outcomes in the International Cooperative Pulmonary Embolism Registry (ICOPER). *Lancet* 1999; 353:1386-1389
- 13 Kasper W, Konstantinides S, Geibel A, et al. Management strategies and determinants of outcome in acute major pulmonary embolism: results of a multicenter registry. *J Am Coll Cardiol* 1997; 30:1165-1171
- 14 Donaldson GA, Williams C, Scannell JGSR. A re-appraisal of the application of the Trendelenburg operation to massive fatal embolism: report of successful pulmonary-artery thrombectomy using a cardiopulmonary bypass. *N Engl J Med* 1963; 268:171-174
- 15 Soloff LA, Rodman T. Acute pulmonary embolism: II. Clinical. *Am Heart J* 1967; 74:829-847
- 16 Tibbutt DA, Davies JA, Anderson JA, et al. Comparison by controlled clinical trial of streptokinase and heparin in treatment of life-threatening pulmonary embolism. *BMJ* 1974; 1:343-347
- 17 Morrison MCT. Is pulmonary embolectomy obsolete? *Br J Dis Chest* 1963; 57:187-191
- 18 Gifford RW Jr, Groves LK. Limitations in the feasibility of pulmonary embolectomy: a clinicopathologic study of 101 cases of massive pulmonary embolism. *Circulation* 1969; 39:523-530
- 19 Turnier E, Hill JD, Kerth WJ, et al. Massive pulmonary embolism. *Am J Surg* 1973; 125:611-622
- 20 Hermann RE, Davis JH, Holden WD. Pulmonary embolism: a clinical and pathological study with emphasis on the

- effect of prophylactic therapy with anticoagulants. *Am J Surg* 1961; 102:19–28
- 21 Neuhoﬀ H. Venous thrombosis and pulmonary embolism. New York, NY: Grune and Stratton, 1948
 - 22 Hoagland PM. Massive pulmonary embolism: pulmonary embolism and deep vein thrombosis. Philadelphia, PA: WB Saunders, 1985; 179–208
 - 23 Belt TH. Thrombosis and pulmonary embolism. *Am J Pathol* 1934; 10:129–144
 - 24 Gorham LW. A study of pulmonary embolism: two the mechanism of death based on a clinical pathological investigation of 100 cases of massive and 285 cases of minor embolism of the pulmonary artery. *Arch Intern Med* 1961; 108:76–90
 - 25 Modan B, Sharon E, Jelin N. Factors contributing to the incorrect diagnosis of pulmonary embolic disease. *Chest* 1972; 62:388–393
 - 26 Morgenthaler TI, Ryu JH. Clinical characteristics of fatal pulmonary embolism in a referral hospital. *Mayo Clin Proc* 1995; 70:417–424
 - 27 Morpurgo M, Schmid C. Clinicopathological correlations in pulmonary embolism: a *posteriori* evaluation. *Prog Respir Dis* 1980; 13:8–15
 - 28 Morpurgo M, Rustici A. The clinical picture of pulmonary embolism. *Cardiologia* 1988; 33:1105–1108
 - 29 Morpurgo M, Schmid C. The spectrum of pulmonary embolism: clinicopathologic correlations. *Chest* 1995; 107(suppl):18S–20S
 - 30 Smith GT, Dammin GJ, Dexter L. Postmortem arteriographic studies of the human lung in pulmonary embolization. *JAMA* 1964; 188:143–151
 - 31 Uhland H, Goldberg LM. Pulmonary embolism: a commonly missed clinical entity. *Dis Chest* 1964; 45:533–536
 - 32 Miller GA, Sutton GC. Acute massive pulmonary embolism: clinical and haemodynamic findings in 23 patients studied by cardiac catheterization and pulmonary arteriography. *Br Heart J* 1970; 32:518–523
 - 33 McIntyre KM, Sasahara AA. Correlation of pulmonary photoscan and angiogram as measures of the severity of pulmonary embolic involvement. *J Nucl Med* 1971; 12:732–738
 - 34 Dalen JE, Dexter L. Diagnosis and management of massive pulmonary embolism. *Dis Mon* 1967; 1–34
 - 35 Urokinase Pulmonary Embolism Trial. Phase 1 results: a cooperative study. *JAMA* 1970; 214:2163–2172
 - 36 Del Guercio LRM, Cohn JDFNR. Pulmonary embolism shock: physiologic basis of a bedside screening test. *JAMA* 1960; 196:751–756
 - 37 McDonald IG, Hirsh J, Hale GS, et al. Major pulmonary embolism, a correlation of clinical findings, haemodynamics, pulmonary angiography, and pathological physiology. *Br Heart J* 1972; 34:356–364
 - 38 Sasahara AA. Pulmonary vascular responses to thromboembolism. *Mod Concepts Cardiovasc Dis* 1967; 36:55–60
 - 39 Alpert JS, Smith R, Carlson J, et al. Mortality in patients treated for pulmonary embolism. *JAMA* 1976; 236:1477–1480
 - 40 Comess KA, DeRook FA, Russell ML, et al. The incidence of pulmonary embolism in unexplained sudden cardiac arrest with pulseless electrical activity. *Am J Med* 2000; 109:351–356
 - 41 Goldhaber SZ, Haire WD, Feldstein ML, et al. Alteplase versus heparin in acute pulmonary embolism: randomized trial assessing right-ventricular function and pulmonary perfusion. *Lancet* 1993; 341:507–511
 - 42 Thames MD, Alpert JS, Dalen JE. Syncope in patients with pulmonary embolism. *JAMA* 1977; 238:2509–2511
 - 43 Giuntini C, Marini C, di Ricco G, et al. A controlled clinical trial on the effect of heparin infusion and two regimens of urokinase in acute pulmonary embolism. *G Ital Cardiol* 1984; 14(suppl):26–29
 - 44 Meyer G, Sors H, Charbonnier B, et al. Effects of intravenous urokinase versus alteplase on total pulmonary resistance in acute massive pulmonary embolism: a European multicenter double-blind trial; the European Cooperative Study Group for Pulmonary Embolism. *J Am Coll Cardiol* 1992; 19:239–245
 - 45 Marini C, di Ricco G, Rossi G, et al. Fibrinolytic effects of urokinase and heparin in acute pulmonary embolism: a randomized clinical trial. *Respiration* 1988; 54:162–173
 - 46 Sors H, Pacouret G, Azarian R, et al. Hemodynamic effects of bolus vs 2-h infusion of alteplase in acute massive pulmonary embolism: a randomized controlled multicenter trial. *Chest* 1994; 106:712–717
 - 47 Dalla-Volta S, Palla A, Santolicandro A, et al. PAIMS 2: alteplase combined with heparin versus heparin in the treatment of acute pulmonary embolism; plasminogen activator Italian multicenter study 2. *J Am Coll Cardiol* 1992; 20:520–526
 - 48 PIOPED Investigators. Tissue plasminogen activator for the treatment of acute pulmonary embolism: a collaborative study by the PIOPED Investigators. *Chest* 1990; 97:528–533
 - 49 Guyton AC, Jones CE, Coleman TG. Circulatory physiology: cardiac output and its regulation. In: Guyton AC, ed. *Physiology*. Philadelphia, PA: WB Saunders, 1973
 - 50 Pulmonary Artery Catheter Consensus Conference: Chicago, Illinois, December 6–8, 1996. *New Horiz* 1997; 5:173–292
 - 51 Dalen JE, Haynes FW, Hoppin FG, et al. Cardiovascular responses to experimental pulmonary embolism. *Am J Cardiol* 1967; 20:3–9
 - 52 McIntyre KM, Sasahara AA. Hemodynamic and ventricular responses to pulmonary embolism. *Prog Cardiovasc Dis* 1974; 17:175–190
 - 53 Parker BM, Smith JR. Pulmonary embolism and infarction: a review of the physiologic consequences of pulmonary artery obstruction. *Am J Med* 1958; 24:402–427
 - 54 Stein M, Levy SE. Reflex and humoral responses to pulmonary embolism. *Prog Cardiovasc Dis* 1974; 17:167–174
 - 55 Malik AB. Pulmonary microembolism. *Physiol Rev* 1983; 63:1114–1207
 - 56 Alpert JS, Godtfredsen J, Ockene IS, et al. Pulmonary hypertension secondary to minor pulmonary embolism. *Chest* 1978; 73:795–797
 - 57 Calvin JE Jr, Baer RW, Glantz SA. Pulmonary artery constriction produces a greater right ventricular dynamic afterload than lung microvascular injury in the open chest dog. *Circ Res* 1985; 56:40–56
 - 58 Stein PD, Sabbah HN, Anbe DT, et al. Performance of the failing and nonfailing right ventricle of patients with pulmonary hypertension. *Am J Cardiol* 1979; 44:1050–1055
 - 59 Calvin JE, Quinn B. Right ventricular pressure overload during acute lung injury: cardiac mechanisms and the pathophysiology of right ventricular systolic dysfunction. *J Crit Care* 1989; 4:251–265
 - 60 Calvin JE Jr. Acute right heart failure: pathophysiology, recognition, and pharmacological management. *J Cardiothorac Vasc Anesth* 1991; 5:507–513
 - 61 Taylor RR, Covell JW, Sonnenblick EH, et al. Dependence of ventricular distensibility on filling of the opposite ventricle. *Am J Physiol* 1967; 213:711–718
 - 62 Jardin F, Dubourg O, Gueret P, et al. Quantitative two-dimensional echocardiography in massive pulmonary embolism.

- lism: emphasis on ventricular interdependence and leftward septal displacement. *J Am Coll Cardiol* 1987; 10:1201–1206
- 63 Belenkie I, Dani R, Smith ER, et al. Ventricular interaction during experimental acute pulmonary embolism. *Circulation* 1988; 78:761–768
 - 64 Dack S, Master AM, Horn H, et al. Acute coronary insufficiency due to pulmonary embolism. *Am J Med* 1949; 7:464–477
 - 65 Watanabe J, Levine MJ, Bellotto F, et al. Effects of coronary venous pressure on left ventricular diastolic distensibility. *Circ Res* 1990; 67:923–932
 - 66 Vlahakes GJ, Turley K, Hoffman JI. The pathophysiology of failure in acute right ventricular hypertension: hemodynamic and biochemical correlations. *Circulation* 1981; 63: 87–95
 - 67 Coma-Canella I, Gamallo C, Martinez OP, et al. Acute right ventricular infarction secondary to massive pulmonary embolism. *Eur Heart J* 1988; 9:534–540
 - 68 Adams JE III, Siegel BA, Goldstein JA, et al. Elevations of CK-MB following pulmonary embolism: a manifestation of occult right ventricular infarction. *Chest* 1992; 101:1203–1206
 - 69 Jerjes-Sanchez C, Ramirez-Rivera A, de Lourdes GM, et al. Streptokinase and heparin versus heparin alone in massive pulmonary embolism: a randomized controlled trial. *J Thromb Thrombolysis* 1995; 2:227–229
 - 70 Prewitt RM. Hemodynamic management in pulmonary embolism and acute hypoxemic respiratory failure. *Crit Care Med* 1990; 18(suppl):S61–S69
 - 71 D'Alonzo GE, Dantzker DR. Gas exchange alterations following pulmonary thromboembolism. *Clin Chest Med* 1984; 5:411–419
 - 72 Levy SE, Stein M, Totten RS, et al. Ventilation-perfusion abnormalities in experimental pulmonary embolism. *J Clin Invest* 1965; 44:1699–1707
 - 73 Wilson JE III, Pierce AK, Johnson RL Jr, et al. Hypoxemia in pulmonary embolism, a clinical study. *J Clin Invest* 1971; 50:481–491
 - 74 D'Alonzo GE, Bower JS, DeHart P, et al. The mechanisms of abnormal gas exchange in acute massive pulmonary embolism. *Am Rev Respir Dis* 1983; 128:170–172
 - 75 Manier G, Castaing Y, Guenard H. Determinants of hypoxemia during the acute phase of pulmonary embolism in humans. *Am Rev Respir Dis* 1985; 132:332–338
 - 76 Huet Y, Lemaire F, Brun-Buisson C, et al. Hypoxemia in acute pulmonary embolism. *Chest* 1985; 88:829–836
 - 77 Santolucando A, Prediletto R, Fornai E, et al. Mechanisms of hypoxemia and hypocapnia in pulmonary embolism. *Am J Respir Crit Care Med* 1995; 152:336–347
 - 78 Dantzker DR, Wagner PD, Tornabene VW, et al. Gas exchange after pulmonary thromboembolization in dogs. *Circ Res* 1978; 42:92–103
 - 79 Chernick V, Hodson WA, Greenfield LJ. Effect of chronic pulmonary artery ligation on pulmonary mechanics and surfactant. *J Appl Physiol* 1966; 21:1315–1320
 - 80 Levy SE, Simmons DH. Redistribution of alveolar ventilation following pulmonary thromboembolism in the dog. *J Appl Physiol* 1974; 36:60–68
 - 81 Levy SE, Simmons DH. Mechanism of arterial hypoxemia following pulmonary thromboembolism in dogs. *J Appl Physiol* 1975; 39:41–46
 - 82 Moorthy SS, Losasso AM, Gibbs PS. Acquired right to left intracardiac shunt in severe hypoxemia. *Crit Care Med* 1978; 6:28–31
 - 83 Jardin F, Gurdjian F, Desfonds P, et al. Hemodynamic factors influencing arterial hypoxemia in massive pulmonary embolism with circulatory failure. *Circulation* 1979; 59:909–912
 - 84 Dalen JE, Banas JS Jr, Brooks HL, et al. Resolution rate of acute pulmonary embolism in man. *N Engl J Med* 1969; 280:1194–1199
 - 85 McIntyre KM, Sasahara AA. The hemodynamic response to pulmonary embolism in patients without prior cardiopulmonary disease. *Am J Cardiol* 1971; 28:288–294
 - 86 Dalen JE, Grossman W. Profiles in pulmonary embolism: cardiac catheterization and angiography. Philadelphia, PA: Lea and Febiger, 1980
 - 87 Brandfonbrener M, Turino GM, Himmelstein A, et al. Effects of occlusion of one pulmonary artery on pulmonary circulation in man. *Fed Proc* 1958; 17(suppl):19
 - 88 Benotti JR, Dalen JE. The natural history of pulmonary embolism. *Clin Chest Med* 1984; 5:403–410
 - 89 Petitpretz P, Simmoneau G, Cerrina J, et al. Effects of a single bolus of urokinase in patients with life-threatening pulmonary emboli: a descriptive trial. *Circulation* 1984; 70:861–866
 - 90 Kontos HA, Levasseur JE, Richardson DW, et al. Comparative circulatory responses to systemic hypoxia in man and in unanesthetized dog. *J Appl Physiol* 1967; 23:381–386
 - 91 Eckstein JW, Harsley AW. Effects of hypoxia on peripheral venous tone in man. *J Lab Clin Med* 1960; 56:847–853
 - 92 McIntyre KM, Sasahara AA. Determinants of right ventricular function and hemodynamics after pulmonary embolism. *Chest* 1974; 65:534–543
 - 93 UKEP Study Research Group. The UKEP study: multicentre clinical trial on two local regimens of urokinase in massive pulmonary embolism. *Eur Heart J* 1987; 8:2–10
 - 94 Ducas J, Prewitt RM. Pathophysiology and therapy of right ventricular dysfunction due to pulmonary embolism. *Cardiovasc Clin* 1987; 17:191–202
 - 95 McIntyre KM, Sasahara AA. The ratio of pulmonary arterial pressure to pulmonary vascular obstruction: index of pre-embolic cardiopulmonary status. *Chest* 1977; 71:692–697
 - 96 Urokinase-Streptokinase Embolism Trial. Phase 2 results: a cooperative study. *JAMA* 1974; 229:1606–1613
 - 97 Stein PD, Terrin ML, Hales CA, et al. Clinical, laboratory, roentgenographic, and electrocardiographic findings in patients with acute pulmonary embolism and no pre-existing cardiac or pulmonary disease. *Chest* 1991; 100:598–603
 - 98 Stein PD. The history and physical examination in patients with no prior cardiopulmonary disease: pulmonary embolism. Baltimore, MD: Williams and Wilkins, 1996; 41–53
 - 99 Stein PD. The history and physical examination in all patients irrespective of prior cardiopulmonary disease: pulmonary embolism. Baltimore, MD: Williams and Wilkins, 1996; 54–58
 - 100 Miller GA, Hall RJ, Paneth M. Pulmonary embolectomy, heparin, and streptokinase: their place in the treatment of acute massive pulmonary embolism. *Am Heart J* 1977; 93:568–574
 - 101 Stein PD, Henry JW. Clinical characteristics of patients with acute pulmonary embolism stratified according to their presenting syndromes. *Chest* 1997; 112:974–979
 - 102 Stein PD, Willis PW III, DeMets DL. History and physical examination in acute pulmonary embolism in patients without preexisting cardiac or pulmonary disease. *Am J Cardiol* 1981; 47:218–223
 - 103 Bell WR, Simon TL, DeMets DL. The clinical features of submassive and massive pulmonary emboli. *Am J Med* 1977; 62:355–360
 - 104 Quintana E, Sanchez JM, Serra C, et al. Erroneous interpretation of pulmonary capillary wedge pressure in massive pulmonary embolism. *Crit Care Med* 1983; 11:933–935

- 105 Jardin F, Dubourg O, Bourdarias JP. Echocardiographic pattern of acute cor pulmonale. *Chest* 1997; 111:209–217
- 106 Machida K, Rapaport E. Left ventricular function in experimental pulmonary embolism. *Jpn Heart J* 1971; 12:221–232
- 107 Rosendaal FR. Risk factors for venous thrombotic disease. *Thromb Haemost* 1999; 82:610–619
- 108 McGinn S, White PD. Acute cor pulmonale resulting from pulmonary embolism. *JAMA* 1935; 104:1473–1480
- 109 Stein PD, Dalen JE, McIntyre KM, et al. The electrocardiogram in acute pulmonary embolism. *Prog Cardiovasc Dis* 1975; 17:247–257
- 110 Szucs MM Jr, Brooks HL, Grossman W, et al. Diagnostic sensitivity of laboratory findings in acute pulmonary embolism. *Ann Intern Med* 1971; 74:161–166
- 111 Lui CY. Acute pulmonary embolism as the cause of global T wave inversion and QT prolongation: a case report. *J Electrocardiol* 1993; 26:91–95
- 112 Ahonen A. Electrocardiographic changes in massive pulmonary embolism: II. Analysis of the changes in ST segment and T wave. *Acta Med Scand* 1977; 201:543–545
- 113 Yoshinaga T, Ikeda S, Nishimura E, et al. Serial changes in negative T wave on electrocardiogram in acute pulmonary thromboembolism. *Int J Cardiol* 1999; 72:65–72
- 114 Ferrari E, Imbert A, Chevalier T, et al. The ECG in pulmonary embolism: predictive value of negative T waves in precordial leads; 80 case reports. *Chest* 1997; 111:537–543
- 115 Cathforth RH, Oram S. The electrocardiogram in pulmonary embolism. *Br Heart J* 1958; 20:41–54
- 116 Nielsen TT, Lund O, Ronne K, et al. Changing electrocardiographic findings in pulmonary embolism in relation to vascular obstruction. *Cardiology* 1989; 76:274–284
- 117 McIntyre KM, Sasahara AA, Littmann D. Relation of the electrocardiogram to hemodynamic alterations in pulmonary embolism. *Am J Cardiol* 1972; 30:205–210
- 118 Love WS, Brugler GW, Winslow N. Electrocardiographic studies in clinical and experimental pulmonary embolism. *Ann Intern Med* 1938; 11:2109–2123
- 119 Sreeram N, Cherix EC, Smeets JL, et al. Value of the 12-lead electrocardiogram at hospital admission in the diagnosis of pulmonary embolism. *Am J Cardiol* 1994; 73:298–303
- 120 Oram S. Acute pulmonary embolism mimicking coronary artery disease. *Lancet* 1962; 2:1076–1079
- 121 Horn H, Dack S, Friedberg CK. Cardiac sequelae of embolism of the pulmonary artery. *Arch Intern Med* 1939; 64:296–321
- 122 Meyers G. QRS-T patterns in multiple precordial leads that may be mistaken for myocardial infarction. *Circulation* 1950; 1:1860–1872
- 123 Wood P. Pulmonary embolism: diagnosis by chest lead electrocardiography. *Br Heart J* 1941; 3:21–29
- 124 Ferrari E, Imbert A, Darcourt J. No scintigraphic evidence of myocardial abnormality in severe pulmonary embolism with electrocardiographic signs of anterior ischemia [abstract]. *Eur Heart J* 1995; 16(suppl):269
- 125 Stein PD, Athanasoulis C, Greenspan RH, et al. Relation of plain chest radiographic findings to pulmonary arterial pressure and arterial blood oxygen levels in patients with acute pulmonary embolism. *Am J Cardiol* 1992; 69:394–396
- 126 Stein PD, Willis PWI, DeMets DL. Plain chest roentgenogram in patients with acute pulmonary embolism and no pre-existing cardiac or pulmonary disease. *Am J Noninvasive Cardiol* 1987; 1:171–176
- 127 Kerr IH, Simon G, Sutton GC. The value of the plain radiograph in acute massive pulmonary embolism. *Br J Radiol* 1971; 44:751–757
- 128 Stein PD, Goldhaber SZ, Henry JW, et al. Arterial blood gas analysis in the assessment of suspected acute pulmonary embolism. *Chest* 1996; 109:78–81
- 129 Urokinase Pulmonary Embolism Trial. *Circulation* 1973; 47(suppl):1–108
- 130 Stein PD, Goldhaber SZ, Henry JW. Alveolar-arterial oxygen gradient in the assessment of acute pulmonary embolism. *Chest* 1995; 107:139–143
- 131 Overton DT, Bocka JJ. The alveolar-arterial oxygen gradient in patients with documented pulmonary embolism. *Arch Intern Med* 1988; 148:1617–1619
- 132 Dantzker DR, Bower JS. Alterations in gas exchange following pulmonary thromboembolism. *Chest* 1982; 81:495–501
- 133 Stein PD. Arterial blood gases and the alveolar-arterial oxygen difference: pulmonary embolism. Baltimore, MD: Williams and Wilkins, 1996; 80–90
- 134 Cvitanic O, Marino PL. Improved use of arterial blood gas analysis in suspected pulmonary embolism. *Chest* 1989; 95:48–51
- 135 Lippmann M, Fein A. Pulmonary embolism in the patient with chronic obstructive pulmonary disease: a diagnostic dilemma. *Chest* 1981; 79:39–42
- 136 Goldberg SK, Lipschutz JB, Fein AM, et al. Hypercapnia complicating massive pulmonary embolism. *Crit Care Med* 1984; 12:686–688
- 137 Bouchama A, Curley W, Al Dossary S, et al. Refractory hypercapnia complicating massive pulmonary embolism. *Am Rev Respir Dis* 1988; 138:466–468
- 138 Brill-Edwards P, Lee A. D-dimer testing in the diagnosis of acute venous thromboembolism. *Thromb Haemost* 1999; 82:688–694
- 139 Janssen MC, Wollersheim H, Verbruggen B, et al. Rapid D-dimer assays to exclude deep venous thrombosis and pulmonary embolism: current status and new developments. *Semin Thromb Hemost* 1998; 24:393–400
- 140 de Moerloose P, Michiels JJ, Bounameaux H. The place of D-dimer testing in an integrated approach of patients suspected of pulmonary embolism. *Semin Thromb Hemost* 1998; 24:409–412
- 141 Kline J, Meek S, Bondrow D. Use of alveolar dead space fraction (Vd/Vt) and plasma D-dimers to exclude acute pulmonary embolism in ambulatory patients. *Acad Emerg Med* 1997; 4:856–863
- 142 Robin ED, Forkner CE, Bromberg PA. Alveolar gas exchange in clinical pulmonary embolism. *N Engl J Med* 1960; 262:283–287
- 143 Fletcher R, Jonson B. Dead space and the single breath test for carbon dioxide during anesthesia and artificial ventilation. *Br J Anaesth* 1994; 56:109–119
- 144 Eriksson L, Wollmer P, Olsson CG, et al. Diagnosis of pulmonary embolism based upon alveolar dead space analysis. *Chest* 1989; 96:357–362
- 145 Burki NK. The dead space to tidal volume ratio in the diagnosis of pulmonary embolism. *Am Rev Respir Dis* 1986; 133:679–685
- 146 Anderson JT, Owings JT, Goodnight JE. Bedside noninvasive detection of acute pulmonary embolism in critically ill surgical patients. *Arch Surg* 1999; 134:869–874
- 147 Rodger MA, Jones G, Raymond F, et al. Dead space ventilation parallels changes in scintigraphic vascular obstruction at recurrence of pulmonary embolism and after thrombolytic therapy: a case report. *Can Respir J* 1998; 5:215–218
- 148 Goldhaber SZ. The perils of D-dimer in the medical intensive care unit. *Crit Care Med* 2000; 28:583–584
- 149 Becker DM, Philbrick JT, Bachhuber TL, et al. D-dimer

- testing and acute venous thromboembolism: a shortcut to accurate diagnosis? *Arch Intern Med* 1996; 156:939–946
- 150 Bounameaux H, de Moerloose P, Perrier A, et al. Plasma measurement of D-dimer as diagnostic aid in suspected venous thromboembolism: an overview. *Thromb Haemost* 1994; 71:1–6
 - 151 Ginsberg JS, Wells PS, Kearon C, et al. Sensitivity and specificity of a rapid whole-blood assay for D-dimer in the diagnosis of pulmonary embolism. *Ann Intern Med* 1998; 129:1006–1011
 - 152 Miniati M, Prediletto R, Formichi B, et al. Accuracy of clinical assessment in the diagnosis of pulmonary embolism. *Am J Respir Crit Care Med* 1999; 159:864–871
 - 153 Miniati M, Pistolesi M, Marini C, et al. Value of perfusion lung scan in the diagnosis of pulmonary embolism: results of the Prospective Investigative Study of Acute Pulmonary Embolism Diagnosis (PISA-PED). *Am J Respir Crit Care Med* 1996; 154:1387–1393
 - 154 PIOPED Investigators. Value of the ventilation/perfusion scan in acute pulmonary embolism: results of the prospective investigation of pulmonary embolism diagnosis (PIO-PED). *JAMA* 1990; 263:2753–2759
 - 155 Diehl JL, Meyer G, Igual J, et al. Effectiveness and safety of bolus administration of alteplase in massive pulmonary embolism. *Am J Cardiol* 1992; 70:1477–1480
 - 156 Verstraete M, Miller GA, Bounameaux H, et al. Intravenous and intrapulmonary recombinant tissue-type plasminogen activator in the treatment of acute massive pulmonary embolism. *Circulation* 1988; 77:353–360
 - 157 Tilsner V. Thrombolytic therapy in fulminant pulmonary thromboembolism. *Thorac Cardiovasc Surg* 1991; 39:357–359
 - 158 Meneveau N, Schiele F, Metz D, et al. Comparative efficacy of a two-hour regimen of streptokinase versus alteplase in acute massive pulmonary embolism: immediate clinical and hemodynamic outcome and one-year follow-up. *J Am Coll Cardiol* 1998; 31:1057–1063
 - 159 Ly B, Arnesen H, Eie H, et al. A controlled clinical trial of streptokinase and heparin in the treatment of major pulmonary embolism. *Acta Med Scand* 1978; 203:465–470
 - 160 Lorut C, Ghossains M, Horellou MH, et al. A noninvasive diagnostic strategy including spiral computed tomography in patients with suspected pulmonary embolism. *Am J Respir Crit Care Med* 2000; 162:1413–1418
 - 161 Stein PD, Hull RD, Saltzman HA, et al. Strategy for diagnosis of patients with suspected acute pulmonary embolism. *Chest* 1993; 103:1553–1559
 - 162 Wells PS, Ginsberg JS, Anderson DR, et al. Use of a clinical model for safe management of patients with suspected pulmonary embolism. *Ann Intern Med* 1998; 129:997–1005
 - 163 Kearn C, Ginsberg JS, Hirsh J. The role of venous ultrasonography in the diagnosis of suspected deep venous thrombosis and pulmonary embolism. *Ann Intern Med* 1998; 129:1044–1049
 - 164 Girard P, Musset D, Parent F, et al. High prevalence of detectable deep venous thrombosis in patients with acute pulmonary embolism. *Chest* 1999; 116:903–908
 - 165 Hull RD, Hirsh J, Carter CJ, et al. Pulmonary angiography, ventilation lung scanning, and venography for clinically suspected pulmonary embolism with abnormal perfusion lung scan. *Ann Intern Med* 1983; 98:891–899
 - 166 Kruit WH, de Boer AC, Sing AK, et al. The significance of venography in the management of patients with clinically suspected pulmonary embolism. *J Intern Med* 1991; 230:333–339
 - 167 Perrier A, Desmarais S, Goehring C, et al. D-dimer testing for suspected pulmonary embolism in outpatients. *Am J Respir Crit Care Med* 1997; 156:492–496
 - 168 Turkstra F, Kuijter PM, van Beek EJ, et al. Diagnostic utility of ultrasonography of leg veins in patients suspected of having pulmonary embolism. *Ann Intern Med* 1997; 126:775–781
 - 169 Come PC. Echocardiographic evaluation of pulmonary embolism and its response to therapeutic interventions. *Chest* 1992; 101(suppl):151S–162S
 - 170 Konstantinides S, Geibel A, Kasper W. Role of cardiac ultrasound in the detection of pulmonary embolism. *Semin Respir Crit Care Med* 1996; 17:39–49
 - 171 Torbicki A, Tramarin R, Morpurgo M. Role of echo/Doppler in the diagnosis of pulmonary embolism. *Clin Cardiol* 1992; 15:805–810
 - 172 Cheriex EC, Sreeram N, Eussen YF, et al. Cross sectional Doppler echocardiography as the initial technique for diagnosis of acute pulmonary embolism. *Br Heart J* 1994; 72:52–57
 - 173 Kasper W, Meinertz T, Henkel B, et al. Echocardiographic findings in patients with proved pulmonary embolism. *Am Heart J* 1986; 112:1284–1290
 - 174 Nazeyrollas P, Metz D, Jolly D, et al. Use of transthoracic Doppler echocardiography combined with clinical and electrocardiographic data to predict acute pulmonary embolism. *Eur Heart J* 1996; 17:779–786
 - 175 Konstantinides S, Geibel A, Kasper W, et al. Patent foramen ovale is an important predictor of adverse outcome in patients with major pulmonary embolism. *Circulation* 1998; 97:1946–1951
 - 176 Kasper W, Geibel A, Tiede N, et al. Echocardiography in the diagnosis of lung embolism. *Herz* 1989; 14:82–101
 - 177 Metz D, Chapoutot L, Ouzan J, et al. Doppler echocardiographic assessment of the severity of acute pulmonary embolism: a correlative angiographic study in 48 adult patients. *Am J Noninvasive Cardiol* 1991; 5:223–228
 - 178 Kasper W, Meinertz T, Kersting F, et al. Echocardiography in assessing acute pulmonary hypertension due to pulmonary embolism. *Am J Cardiol* 1980; 45:567–572
 - 179 Kasper W, Geibel A, Tiede N, et al. Distinguishing between acute and subacute massive pulmonary embolism by conventional and Doppler echocardiography. *Br Heart J* 1993; 70:352–356
 - 180 Ribeiro A, Lindmarker P, Juhlin-Dannfelt A, et al. Echocardiography Doppler in pulmonary embolism: right ventricular dysfunction as a predictor of mortality rate. *Am Heart J* 1997; 134:479–487
 - 181 Wolfe MW, Lee RT, Feldstein ML, et al. Prognostic significance of right ventricular hypokinesis and perfusion lung scan defects in pulmonary embolism. *Am Heart J* 1994; 127:1371–1375
 - 182 Ribeiro A, Juhlin-Dannfelt A, Brodin LA, et al. Pulmonary embolism: relation between the degree of right ventricle overload and the extent of perfusion defects. *Am Heart J* 1998; 135:868–874
 - 183 Miller RL, Das S, Anandarangam T, et al. Association between right ventricular function and perfusion abnormalities in hemodynamically stable patients with acute pulmonary embolism. *Chest* 1998; 113:665–670
 - 184 Torbicki A, Pruszczyk P, Chlebus M. Can we proceed to aggressive therapy of suspected severe pulmonary embolism without pulmonary angiography? *Cor Vasa* 1995; 37:82–86
 - 185 ACCP Consensus Committee on Pulmonary Embolism. Opinions regarding the diagnosis and management of venous thromboembolic disease. *Chest* 1996; 109:233–237
 - 186 Konstantinides S, Geibel A, Kasper W. Submassive and

- massive pulmonary embolism: a target for thrombolytic therapy? *Thromb Haemost* 1999; 82(suppl):104–108
- 187 Grifoni S, Olivetto I, Cecchini P, et al. Utility of an integrated clinical, echocardiographic, and venous ultrasonographic approach for triage of patients with suspected pulmonary embolism. *Am J Cardiol* 1998; 82:1230–1235
 - 188 Vardan S, Mookherjee S, Smulyan HS, et al. Echocardiography in pulmonary embolism. *Jpn Heart J* 1983; 24:67–78
 - 189 Currie PJ, Seward JB, Chan KL, et al. Continuous wave Doppler determination of right ventricular pressure: a simultaneous Doppler-catheterization study in 127 patients. *J Am Coll Cardiol* 1985; 6:750–756
 - 190 Kasper W, Konstantinides S, Geibel A, et al. Prognostic significance of right ventricular afterload stress detected by echocardiography in patients with clinically suspected pulmonary embolism. *Heart* 1997; 77:346–349
 - 191 Nazeyrollas P, Metz D, Chapoutot L, et al. Diagnostic accuracy of echocardiography-Doppler in acute pulmonary embolism. *Int J Cardiol* 1995; 47:273–280
 - 192 Torbicki A, Kurzyna M, Ciurzynski M, et al. Proximal pulmonary emboli modify right ventricular ejection pattern. *Eur Respir J* 1999; 13:616–621
 - 193 McConnell MV, Solomon SD, Rayan ME, et al. Regional right ventricular dysfunction detected by echocardiography in acute pulmonary embolism. *Am J Cardiol* 1996; 78:469–473
 - 194 Pruszczyk P, Torbicki A, Pacho R, et al. Noninvasive diagnosis of suspected severe pulmonary embolism: transesophageal echocardiography vs spiral CT. *Chest* 1997; 112:722–728
 - 195 Steiner P, Lund GK, Debatin JF, et al. Acute pulmonary embolism: value of transthoracic and transesophageal echocardiography in comparison with helical CT. *AJR Am J Roentgenol* 1996; 167:931–936
 - 196 Wittlich N, Erbel R, Eichler A, et al. Detection of central pulmonary artery thromboemboli by transesophageal echocardiography in patients with severe pulmonary embolism. *J Am Soc Echocardiogr* 1992; 5:515–524
 - 197 Vieillard-Baron A, Qanadli SD, Antakly Y, et al. Transesophageal echocardiography for the diagnosis of pulmonary embolism with acute cor pulmonale: a comparison with radiological procedures. *Intensive Care Med* 1998; 24:429–433
 - 198 Pruszczyk P, Torbicki A, Kuch-Wocial A, et al. Transoesophageal echocardiography for definitive diagnosis of haemodynamically significant pulmonary embolism. *Eur Heart J* 1995; 16:534–538
 - 199 van der Wouw PA, Koster RW, Delemarre BJ, et al. Diagnostic accuracy of transesophageal echocardiography during cardiopulmonary resuscitation. *J Am Coll Cardiol* 1997; 30:780–783
 - 200 Varriale P, Maldonado JM. Echocardiographic observations during in hospital cardiopulmonary resuscitation. *Crit Care Med* 1997; 25:1717–1720
 - 201 Lesser BA, Leeper KV Jr, Stein PD, et al. The diagnosis of acute pulmonary embolism in patients with chronic obstructive pulmonary disease. *Chest* 1992; 102:17–22
 - 202 Stein PD, Coleman RE, Gottschalk A, et al. Diagnostic utility of ventilation/perfusion lung scans in acute pulmonary embolism is not diminished by pre-existing cardiac or pulmonary disease. *Chest* 1991; 100:604–606
 - 203 Stein PD, Alavi A, Gottschalk A, et al. Usefulness of noninvasive diagnostic tools for diagnosis of acute pulmonary embolism in patients with a normal chest radiograph. *Am J Cardiol* 1991; 67:1117–1120
 - 204 Stein PD. Application of ventilation/perfusion lung scans in specific populations of patients. *Semin Respir Crit Care Med* 1996; 17:23–29
 - 205 Henry JW, Stein PD, Gottschalk A, et al. Scintigraphic lung scans and clinical assessment in critically ill patients with suspected acute pulmonary embolism. *Chest* 1996; 109:462–466
 - 206 Davis LP, Fink-Bennett D. Nuclear medicine in the acutely ill patient: I. *Crit Care Clin* 1994; 10:365–381
 - 207 Stein PD, Terrin ML, Gottschalk A, et al. Value of ventilation/perfusion scans versus perfusion scans alone in acute pulmonary embolism. *Am J Cardiol* 1992; 69:1239–1241
 - 208 Worsley DF, Alavi A. Comprehensive analysis of the results of the PIOPED study: Prospective Investigation of Pulmonary Embolism Diagnosis Study. *J Nucl Med* 1995; 36:2380–2387
 - 209 Stein PD, Athanasoulis C, Alavi A, et al. Complications and validity of pulmonary angiography in acute pulmonary embolism. *Circulation* 1992; 85:462–468
 - 210 Cooper TJ, Hayward MW, Hartog M. Survey on the use of pulmonary scintigraphy and angiography for suspected pulmonary thromboembolism in the UK. *Clin Radiol* 1991; 43:243–245
 - 211 Mills SR, Jackson DC, Older RA, et al. The incidence, etiologies, and avoidance of complications of pulmonary angiography in a large series. *Radiology* 1980; 136:295–299
 - 212 Zuckerman DA, Sterling KM, Oser RF. Safety of pulmonary angiography in the 1990s. *J Vasc Interv Radiol* 1996; 7:199–205
 - 213 Bauer EP, Laske A, von Segesser LK, et al. Early and late results after surgery for massive pulmonary embolism. *Thorac Cardiovasc Surg* 1991; 39:353–356
 - 214 Stein PD, Hull RD, Raskob G. Risks for major bleeding from thrombolytic therapy in patients with acute pulmonary embolism: consideration of noninvasive management. *Ann Intern Med* 1994; 121:313–317
 - 215 Goodman LR, Lipchik RJ. Diagnosis of acute pulmonary embolism: time for a new approach. *Radiology* 1996; 199:25–27
 - 216 Reid JH, Murchison JT. Acute right ventricular dilatation: a new helical CT sign of massive pulmonary embolism. *Clin Radiol* 1998; 53:694–698
 - 217 Cross JJ, Kemp PM, Walsh CG, et al. A randomized trial of spiral CT and ventilation perfusion scintigraphy for the diagnosis of pulmonary embolism. *Clin Radiol* 1998; 53:177–182
 - 218 Coche EE, Muller NL, Kim KI, et al. Acute pulmonary embolism: ancillary findings at spiral CT. *Radiology* 1998; 207:753–758
 - 219 Remy-Jardin M, Remy J, Wattinne L, et al. Central pulmonary thromboembolism: diagnosis with spiral volumetric CT with the single-breath-hold technique: comparison with pulmonary angiography. *Radiology* 1992; 185:381–387
 - 220 Goodman LR, Curtin JJ, Mewissen MW, et al. Detection of pulmonary embolism in patients with unresolved clinical and scintigraphic diagnosis: helical CT versus angiography. *AJR Am J Roentgenol* 1995; 164:1369–1374
 - 221 Remy-Jardin M, Remy J, Deschildre F, et al. Diagnosis of pulmonary embolism with spiral CT: comparison with pulmonary angiography and scintigraphy. *Radiology* 1996; 200:699–706
 - 222 Teigen CL, Maus TP, Sheedy PF, et al. Pulmonary embolism: diagnosis with contrast-enhanced electron-beam CT and comparison with pulmonary angiography. *Radiology* 1995; 194:313–319
 - 223 Blum AG, Delfau F, Grignon B, et al. Spiral-computed tomography versus pulmonary angiography in the diagnosis

- of acute massive pulmonary embolism. *Am J Cardiol* 1994; 74:96–98
- 224 Stein PD, Hull RD, Pineo GF. The role of newer diagnostic techniques in the diagnosis of pulmonary embolism. *Curr Opin Pulm Med* 1999; 5:212–215
- 225 Indik JH, Alpert JS. Detection of pulmonary embolism by D-dimer assay, spiral computed tomography, and magnetic resonance imaging. *Prog Cardiovasc Dis* 2000; 42:261–272
- 226 Torbicki A. Imaging venous thromboembolism with emphasis on ultrasound, chest CT, angiography and echocardiography. *Thromb Haemost* 1999; 82:907–912
- 227 van Rossum AB, Pattynama PM, Ton ER, et al. Pulmonary embolism: validation of spiral CT angiography in 149 patients. *Radiology* 1996; 201:467–470
- 228 Ferretti GR, Bosson JL, Buffaz PD, et al. Acute pulmonary embolism: role of helical CT in 164 patients with intermediate probability at ventilation-perfusion scintigraphy and normal results at duplex US of the legs. *Radiology* 1997; 205:453–458
- 229 Mayo JR, Remy-Jardin M, Muller NL, et al. Pulmonary embolism: prospective comparison of spiral CT with ventilation-perfusion scintigraphy. *Radiology* 1997; 205:447–452
- 230 Drucker EA, Rivitz SM, Shepard JA, et al. Acute pulmonary embolism: assessment of helical CT for diagnosis. *Radiology* 1998; 209:235–241
- 231 Garg K, Welsh CH, Feyerabend AJ, et al. Pulmonary embolism: diagnosis with spiral CT and ventilation-perfusion scanning; correlation with pulmonary angiographic results or clinical outcome. *Radiology* 1998; 208:201–208
- 232 Remy-Jardin M, Remy J, Artaud D, et al. Peripheral pulmonary arteries: optimization of the spiral CT acquisition protocol. *Radiology* 1997; 204:157–163
- 233 Stein PD, Henry JW. Prevalence of acute pulmonary embolism in central and subsegmental pulmonary arteries and relation to probability interpretation of ventilation/perfusion lung scans. *Chest* 1997; 111:1246–1248
- 234 Kuzo RS, Goodman LR. CT evaluation of pulmonary embolism: technique and interpretation. *AJR Am J Roentgenol* 1997; 169:959–965
- 235 Meany J, Weg J, Chenevert T, et al. Diagnosis of pulmonary embolism with magnetic resonance angiography. *N Engl J Med* 1997; 336:1422–1427
- 236 Loubeyre P, Revel D, Douek P, et al. Dynamic contrast-enhanced MR angiography of pulmonary embolism: comparison with pulmonary angiography. *AJR Am J Roentgenol* 1994; 162:1035–1039
- 237 Erdman W, Peshock R, Redman H, et al. Pulmonary embolism: comparison of MR images with radionuclide and angiographic studies. *Radiology* 1994; 190:499–508
- 238 Geftter WB, Hatabu H, Holland GA, et al. Pulmonary thromboembolism: recent developments in diagnosis with CT and MR imaging. *Radiology* 1995; 197:561–574
- 239 Caldini P. Pulmonary hemodynamics and arterial oxygen saturation in pulmonary embolism. *J Appl Physiol* 1965; 20:184–190
- 240 Murray IV, Mikhail M, Banner MJ, et al. Pulmonary embolism: high frequency jet ventilation offers advantages over conventional mechanical ventilation. *Crit Care Med* 1987; 15:114–117
- 241 Badr MS, Grossman JE. Positional changes in gas exchange after unilateral pulmonary embolism. *Chest* 1990; 98:1514–1516
- 242 Mercat A, Diehl JL, Meyer G, et al. Hemodynamic effects of fluid loading in acute massive pulmonary embolism. *Crit Care Med* 1999; 27:540–544
- 243 Molloy DW, Lee KY, Girling L, et al. Treatment of shock in a canine model of pulmonary embolism. *Am Rev Respir Dis* 1984; 130:870–874
- 244 Ghignoue M, Girling L, Prewitt RM. Volume expansion vs. norepinephrine in treatment of low cardiac output complicating an acute increase in right ventricular afterload in dogs. *Anesthesiology* 1984; 60:132–135
- 245 State D, Salisbury PR. The experimental production of pulmonary embolism syndrome and the effects of variations of systemic arterial pressure on its course. *Surg Gynecol Obstet* 1956; 103:202–208
- 246 Rosenberg JC, Hussain R, Lenaghan R. Isoproterenol and norepinephrine therapy for pulmonary embolism shock. *Thorac Cardiovasc Surg* 1971; 62:144–150
- 247 Mathru M, Venus B, Smith RA, et al. Treatment of low cardiac output complicating acute pulmonary hypertension in normovolemic goats. *Crit Care Med* 1986; 14:120–124
- 248 Hirsch LJ, Rooney MW, Wat SS, et al. Norepinephrine and phenylephrine effects on right ventricular function in experimental canine pulmonary embolism. *Chest* 1991; 100:796–801
- 249 Angle MR, Molloy DW, Penner B, et al. The cardiopulmonary and renal hemodynamic effects of norepinephrine in canine pulmonary embolism. *Chest* 1989; 95:1333–1337
- 250 Jardin F, Genevray B, Brun-Ney D, et al. Dobutamine: a hemodynamic evaluation in pulmonary embolism shock. *Crit Care Med* 1985; 13:1009–1012
- 251 Manier G, Castaing Y. Influence of cardiac output on oxygen exchange in acute pulmonary embolism. *Am Rev Respir Dis* 1992; 145:130–136
- 252 Layish DT, Tapson VF. Pharmacologic hemodynamic support in massive pulmonary embolism. *Chest* 1997; 111:218–224
- 253 Capellier G, Jacques T, Balvay P, et al. Inhaled nitric oxide in patients with pulmonary embolism. *Intensive Care Med* 1997; 23:1089–1092
- 254 Webb SA, Stott S, van Heerden PV. The use of inhaled aerosolized prostacyclin (IAP) in the treatment of pulmonary hypertension secondary to pulmonary embolism. *Intensive Care Med* 1996; 22:353–355
- 255 Goldhaber SZ. Pulmonary embolism. *N Engl J Med* 1998; 339:93–104
- 256 Casthely PA, Yoganathan D, Karyanis B, et al. Histamine blockade and cardiovascular changes following heparin administration during cardiac surgery. *J Cardiothorac Anesth* 1990; 4:711–714
- 257 Kanbak M, Kahraman S, Celebioglu B, et al. Prophylactic administration of histamine 1 and/or histamine 2 receptor blockers in the prevention of heparin- and protamine-related haemodynamic effects. *Anaesth Intensive Care* 1996; 24:559–563
- 258 Kearon C. Initial treatment of venous thromboembolism. *Thromb Haemost* 1999; 82:887–891
- 259 Douketis JD, Kearon C, Bates S, et al. Risk of fatal pulmonary embolism in patients with treated venous thromboembolism. *JAMA* 1998; 279:458–462
- 260 Hull R, Delmore T, Genton E, et al. Warfarin sodium versus low-dose heparin in the long-term treatment of venous thrombosis. *N Engl J Med* 1979; 301:855–858
- 261 Hull RD, Raskob GE, Hirsh J, et al. Continuous intravenous heparin compared with intermittent subcutaneous heparin in the initial treatment of proximal-vein thrombosis. *N Engl J Med* 1986; 315:1109–1114
- 262 Hull RD, Raskob GE, Brant RF, et al. Relation between the time to achieve the lower limit of the APTT therapeutic range and recurrent venous thromboembolism during heparin treatment for deep vein thrombosis. *Arch Intern Med* 1997; 157:2562–2568

- 263 Hull RD, Raskob GE, Brant RF, et al. The importance of initial heparin treatment on long-term clinical outcomes of antithrombotic therapy: the emerging theme of delayed recurrence. *Arch Intern Med* 1997; 157:2317–2321
- 264 Raschke RA, Reilly BM, Guidry JR, et al. The weight-based heparin dosing nomogram compared with a “standard care” nomogram: a randomized controlled trial. *Ann Intern Med* 1993; 119:874–881
- 265 Hull RD, Raskob GE, Rosenbloom D, et al. Heparin for 5 days as compared with 10 days in the initial treatment of proximal venous thrombosis. *N Engl J Med* 1990; 322:1260–1264
- 266 Gallus AS, Jackaman J, Tillett J, et al. Safety and efficiency of warfarin started early after submassive venous thrombosis or pulmonary embolism. *Lancet* 1986; 2:1293–1296
- 267 Bates SM, Hirsh J. Treatment of venous thromboembolism. *Thromb Haemost* 1999; 82:870–877
- 268 Hirsh J, van Aken WG, Gallus AS, et al. Heparin kinetics in venous thrombosis and pulmonary embolism. *Circulation* 1976; 53:691–695
- 269 Levine MN, Hirsh J, Gent M, et al. A randomized trial comparing activated thromboplastin time with heparin assay in patients with acute venous thromboembolism requiring large daily doses of heparin. *Arch Intern Med* 1994; 154:49–56
- 270 Hull RD, Raskob GE, Brant RF, et al. Low-molecular-weight heparin vs heparin in the treatment of patients with pulmonary embolism: American-Canadian Thrombosis Study Group. *Arch Intern Med* 2000; 160:229–236
- 271 Agnelli G, Parise P. Bolus thrombolysis in venous thromboembolism. *Chest* 1992; 101(suppl):172S–182S
- 272 Dalen JE, Alpert JS, Hirsch J. Thrombolytic therapy for pulmonary embolism: is it effective? Is it safe? When is it indicated? *Arch Intern Med* 1997; 157:2550–2556
- 273 Arcasoy SM, Kreit JW. Thrombolytic therapy of pulmonary embolism: a comprehensive review of current evidence. *Chest* 1999; 115:1695–1707
- 274 Anderson D, Levine MN. Thrombolytic therapy for the treatment of acute pulmonary embolism. *Can Med Assoc J* 1992; 146:1317–1324
- 275 Levine M, Hirsh J, Weitz J, et al. A randomized trial of a single bolus dosage regimen of recombinant tissue plasminogen activator in patients with acute pulmonary embolism. *Chest* 1990; 98:1473–1479
- 276 Goldhaber SZ, Kessler CM, Heit JA. Recombinant tissue type plasminogen activator versus a novel dosing regimen of urokinase in acute pulmonary embolism: a randomized controlled multicenter trial. *J Am Coll Cardiol* 1992; 20:24–30
- 277 Goldhaber SZ, Agnelli G, Levine MN. Reduced dose bolus alteplase vs conventional alteplase infusion for pulmonary embolism thrombolysis: an international multicenter randomized trial; the Bolus Alteplase Pulmonary Embolism Group. *Chest* 1994; 106:718–724
- 278 Levine MN. Thrombolytic therapy for venous thromboembolism: complications and contraindications. *Clin Chest Med* 1995; 16:321–328
- 279 Kanter DS, Mikkola KM, Patel SR, et al. Thrombolytic therapy for pulmonary embolism: frequency of intracranial hemorrhage and associated risk factors. *Chest* 1997; 111:1241–1245
- 280 Sasahara AA, Barsamian EM. Another look at pulmonary embolectomy. *Ann Thorac Surg* 1973; 16:317–320
- 281 Elliott GC. Embolectomy, catheter extraction or disruption of pulmonary emboli. *Curr Opin Pulm Med* 1995; 1:298–302
- 282 Doerge HC, Schoendube FA, Loeser H, et al. Pulmonary embolectomy: review of a 15-year experience and role in the age of thrombolytic therapy. *Eur J Cardiothorac Surg* 1996; 10:952–957
- 283 Stulz P, Schlapfer R, Feer R, et al. Decision making in the surgical treatment of massive pulmonary embolism. *Eur J Cardiothorac Surg* 1994; 8:188–193
- 284 Schmid CH, Zietlow ST, Wagner TO, et al. Fulminant pulmonary embolism: symptoms, diagnostics operative technique and results. *Ann Thorac Surg* 1991; 52:1102–1107
- 285 Del Campo C. Pulmonary embolectomy: a review. *Can J Surg* 1985; 28:111–113
- 286 Clark DB. Pulmonary embolectomy re-evaluated. *Ann R Coll Surg Engl* 1981; 63:18–24
- 287 Mattox KL, Feldtman RW, Beall AC Jr, et al. Pulmonary embolectomy for acute massive pulmonary embolism. *Ann Surg* 1982; 195:726–731
- 288 Satter P. Pulmonary embolectomy with the aid of extracorporeal circulation. *Thorac Cardiovasc Surg* 1982; 30:31–35
- 289 Cross FS, Mowlem A. A survey of the current status of pulmonary embolectomy for massive pulmonary embolism. *Circulation* 1967; 35(suppl):I86–I91
- 290 Clarke DB, Abrams LD. Pulmonary embolectomy: a 25 year experience. *Thorac Cardiovasc Surg* 1986; 92:442–445
- 291 Gray HH, Morgan JM, Paneth M, et al. Pulmonary embolectomy for acute massive pulmonary embolism: an analysis of 71 cases. *Br Heart J* 1988; 60:196–200
- 292 Meyer G, Tamisier D, Sors H, et al. Pulmonary embolectomy: a 20-year experience at one center. *Ann Thorac Surg* 1991; 51:232–236
- 293 Meyns B, Sergeant P, Flameng W, et al. Surgery for massive pulmonary embolism. *Acta Cardiol* 1992; 47:487–493
- 294 Kieny R, Charpentier A, Kieny MT. What is the place of pulmonary embolectomy today? *J Cardiovasc Surg (Torino)* 1991; 32:549–554
- 295 Lund O, Nielsen TT, Ronne K, et al. Pulmonary embolism: long-term follow-up after treatment with full-dose heparin, streptokinase or embolectomy. *Acta Med Scand* 1987; 221:61–71
- 296 Greenfield LJ, Proctor MC, Williams DM, et al. Long-term experience with transvenous catheter pulmonary embolectomy. *J Vasc Surg* 1993; 18:450–457
- 297 Timsit F, Reynau DP, Meyer G. Pulmonary embolectomy by catheter device in massive pulmonary embolism. *Chest* 1991; 100:655–658
- 298 Brady AJ, Crake T, Oakley CM. Percutaneous catheter fragmentation and distal dispersion of proximal pulmonary embolus. *Lancet* 1991; 338:1186–1189
- 299 Schmitz-Rode T, Gunther RW. Percutaneous mechanical thrombolysis: a comparative study of various rotational catheter systems. *Invest Radiol* 1991; 26:557–563
- 300 Fava M, Loyola S, Flores P, et al. Mechanical fragmentation and pharmacologic thrombolysis in massive pulmonary embolism. *J Vasc Interv Radiol* 1997; 8:261–266
- 301 Tapson VF, Davidson CJ, Bauman R, et al. Rapid thrombolysis of massive pulmonary emboli without systemic fibrinogenolysis: intraembolic infusion of thrombolytic therapy [abstract]. *Am Rev Respir Dis* 1992; 145:A719
- 302 Goldhaber SZ. A free-floating approach to filters. *Arch Intern Med* 1997; 157:264–265
- 303 Decousus H, Leizorovicz A, Parent F, et al. A clinical trial of vena caval filters in the prevention of pulmonary embolism in patients with proximal deep-vein thrombosis: Prevention du Risque d’Embolie Pulmonaire par Interruption Cave Study Group. *N Engl J Med* 1998; 338:409–415
- 304 Kronik G. The European Cooperative Study on the clinical

- significance of right heart thrombi: European Working Group on Echocardiography. *Eur Heart J* 1989; 10:1046–1059
- 305 Casazza F, Bongarzone A, Centonze F, et al. Prevalence and prognostic significance of right-sided cardiac mobile thrombi in acute massive pulmonary embolism. *Am J Cardiol* 1997; 79:1433–1435
- 306 Farfel Z, Shechter M, Vered Z, et al. Review of echocardiographically diagnosed right heart entrapment of pulmonary emboli-in-transit with emphasis on management. *Am Heart J* 1987; 113:171–178
- 307 Kinney EL, Wright RJ. Efficacy of treatment of patients with echocardiographically detected right-sided heart thrombi: a meta-analysis. *Am Heart J* 1989; 118:569–573
- 308 Bottiger BW. Thrombolysis during cardiopulmonary resuscitation: Fibrinolysis Proteolysis 1997; 11(suppl):93–100
- 309 Lima JA, Guzman PA, Yin FC, et al. Septal geometry in the unloaded living human heart. *Circulation* 1986; 74:463–468
- 310 Marzagalli M, Rietti P, Chirico MA. Cardiac arrest in acute pulmonary embolism: a clinico-pathological study. *G Ital Cardiol* 1994; 24:21–26
- 311 Bottiger BW, Bohrer H, Bach A, et al. Bolus injection of thrombolytic agents during cardiopulmonary resuscitation for massive pulmonary embolism. *Resuscitation* 1994; 28: 45–54
- 312 Bottiger BW, Reim SM, Diezel G, et al. High-dose bolus injection of urokinase: use during cardiopulmonary resuscitation for massive pulmonary embolism. *Chest* 1994; 106: 1281–1283
- 313 Langdon RW, Swicegood WR, Schwartz DA. Thrombolytic therapy of massive pulmonary embolism during prolonged cardiac arrest using recombinant tissue-type plasminogen activator. *Ann Emerg Med* 1989; 18:678–680
- 314 Scholz KH, Tebbe U, Herrmann C, et al. Frequency of complications of cardiopulmonary resuscitation after thrombolysis during acute myocardial infarction. *Am J Cardiol* 1992; 69:724–728
- 315 van Campen LC, van Leeuwen GR, Verheugt FW. Safety and efficacy of thrombolysis for acute myocardial infarction in patients with prolonged out-of-hospital cardiopulmonary resuscitation. *Am J Cardiol* 1994; 73:953–955
- 316 Tenaglia AN, Califf RM, Candela RJ, et al. Thrombolytic therapy in patients requiring cardiopulmonary resuscitation. *Am J Cardiol* 1991; 68:1015–1019
- 317 Ballew KA, Philbrick JT. Causes of variation in reported in-hospital CPR survival: a critical review. *Resuscitation* 1995; 30:203–215
- 318 Konstantinides S, Geibel A, Olschewski M, et al. Association between thrombolytic treatment and the prognosis of hemodynamically stable patients with major pulmonary embolism: results of a multicenter registry. *Circulation* 1997; 96:882–888
- 319 Grifoni S, Olivotto I, Cecchini P, et al. Short-term clinical outcome of patients with acute pulmonary embolism, normal blood pressure, and echocardiographic right ventricular dysfunction. *Circulation* 2000; 101:2817–2822
- 320 Goldhaber SZ. Pulmonary embolism thrombolysis: broadening the paradigm for its administration. *Circulation* 1997; 96:716–718
- 321 Hamel E, Pacouret G, Vincentelli D. Thrombolysis or heparin therapy in massive pulmonary embolism with right ventricular dilation: results from a 128-patient monocenter registry. *Chest* 2001; 120:120–125