

Emergency Neurological Life Support: Subarachnoid Hemorrhage

Jonathan A. Edlow · Owen Samuels ·
Wade S. Smith · Scott D. Weingart

© Neurocritical Care Society 2012

Abstract Subarachnoid hemorrhage (SAH) is a neurological emergency because it may lead to sudden neurological decline and death and, depending on the cause, has treatment options that can return a patient to normal. Because there are interventions that can be life-saving in the first hour of onset, SAH was chosen as an Emergency Neurological Life Support protocol.

Keywords Aneurysm · Ventriculostomy · Hydrocephalus · Protocol

Introduction

Subarachnoid hemorrhage (SAH) is a neurological emergency. Although trauma is the most common cause of blood in the subarachnoid space, this section will focus on non-traumatic SAH, of which the predominant cause is a ruptured intracranial aneurysm or arteriovenous

malformation (AVM). At least half of the remainder of atraumatic SAH cases are caused by non-aneurysmal bleeding from a “perimesencephalic” SAH.

The American Heart Association (AHA) updated guidelines for the evaluation and treatment of patients with SAH in 2012 [1], and the Neurocritical Care Society recently released SAH guidelines as well [2]. These guidelines discuss issues of diagnosis and very early management of SAH upon admission to the emergency department (ED) and provide an evidence based review of SAH Management.

The ENLS suggested algorithm for the initial management of SAH is shown in Fig. 1. Suggested items to complete within the first hour of evaluating a patient with SAH are shown in Table 1.

Clinical Features

The vast majority of patients with SAH experience abrupt onset of a severe headache, which may be associated with a brief loss of consciousness, vomiting, neck pain, or stiffness. In approximately 40–50 % of patients, mental status is normal, and there are no focal neurological deficits. Patients often describe this as the “worst headache of my life” or “like my head is exploding.”

This headache is often referred to as a thunderclap headache, which has a differential diagnosis beyond SAH [3, 4]. The headache is almost always unique, as compared with prior headaches the patient may have had. Some of these patients will have meningismus, which is a physical exam finding to be distinguished from neck pain or stiffness that the patient may have by history. The remaining 50 % of patients have various neurological findings ranging from minor mental status changes to focal deficits

J. A. Edlow (✉)

Department of Emergency Medicine, Beth Israel Deaconess Medical Center, Harvard Medical School, Boston, MA, USA
e-mail: jedlow@bidmc.harvard.edu

O. Samuels

Department of Neurosurgery, Emory University School of Medicine, Atlanta, GA, USA

W. S. Smith

ENLS Course Co-Chair, Department of Neurology, University of California, San Francisco, San Francisco, CA, USA

S. D. Weingart

ENLS Course Co-Chair, Division of ED Critical Care, Mount Sinai School of Medicine, New York, NY, USA
e-mail: scott.weingart@mssm.edu

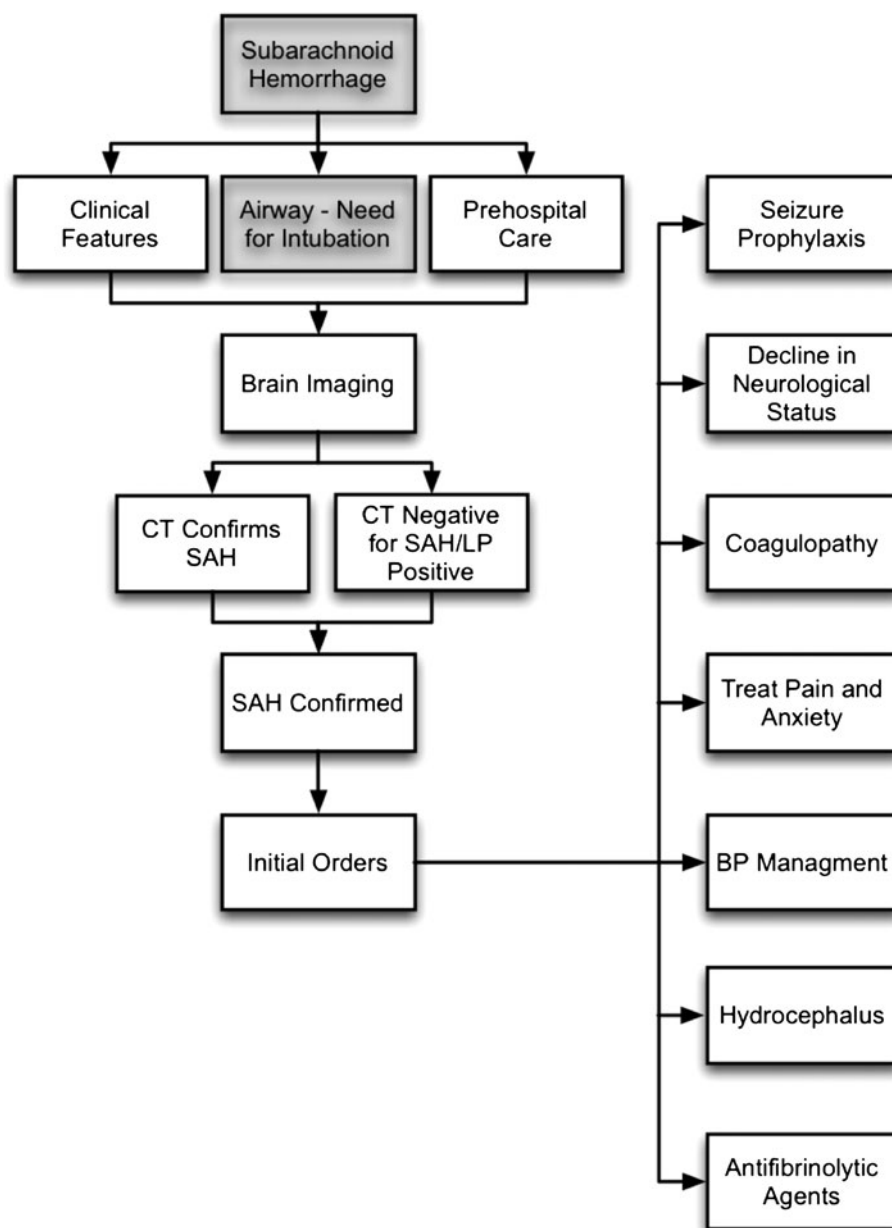


Fig. 1 ENLS Subarachnoid Hemorrhage protocol

Table 1 Subarachnoid hemorrhage checklist for the first hour

- Brain imaging
- Labs: PT, PTT, CBC, platelets, electrolytes, creatinine, troponin, toxicology screen
- 12 lead ECG

associated with the headache. Patients who present comatose will obviously not complain of headache.

Although the classic presentation of SAH includes onset of headache with exertion or a Valsalva maneuver, this finding (headache developing with exertion) actually occurs in a minority of patients, some of whom develop symptoms

during sleep [5]. Some patients with abnormalities in mental status may not be able to give a cogent history of the headache onset. Others may report that the headache did not begin suddenly. A favorable response of the pain to any type of analgesic, including a triptan, should not be used as definitive evidence of a benign etiology [6, 7].

Historic studies suggest that 12–25 % of patients with SAH are misdiagnosed [8] and that approximately 5 % of ED patients with SAH presenting with headache are misdiagnosed on their first visit [9]. Well-appearing patients with normal neurological exams may be mistaken to have migraine or “sinus headache” [3, 8]. In one study, the most common reason for misdiagnosis was failure to perform a

computed tomographic (CT) scan [10]. Not surprisingly, patients with smaller hemorrhages and normal mental status are more often misdiagnosed, and their outcomes are worse than they had been correctly diagnosed [3, 8, 10].

Some SAH patients present with specific symptoms or combinations of symptoms suggest another diagnosis [3, 8]. These include:

- Isolated neck pain (cervical strain or degenerative arthritis).
- Fever and headache (viral syndrome or viral meningitis).
- Prominent nausea and vomiting (gastroenteritis [note the absence of diarrhea] and peripheral vertigo).
- Elevated blood pressure (BP) or electrocardiographic abnormalities (hypertensive encephalopathy or query acute coronary syndrome).

In other situations, a particular physical examination finding, such as a third nerve palsy or a retinal hemorrhage, may suggest the diagnosis of SAH. All patients with a new, severe headache and a new abnormality in their neurological exam should be investigated further.

Among neurologically intact patients, physicians should strongly consider investigating patients with abrupt onset or a severe, unique headache for that patient, especially if the patient exhibits or describes worrisome associated symptoms. One recent, large prospective study that has not yet been independently validated suggested a derivation set of clinical decision rules for which acute severe headache patients require further work-up. The various characteristics found to be predictive of SAH included arrival by ambulance, elevated BP, increased age, vomiting, onset with exertion, loss of consciousness, and neck pain or stiffness [11].

Pre-hospital Care

For patients presenting with isolated headache who are neurologically intact, there are no specific pre-hospital interventions, apart from consideration of analgesics. For patients presenting with headache who are neurologically altered, pre-notification to the ED, and check of a finger stick glucose are important steps. Patients who are severely altered or comatose or are vomiting repeatedly may need to have their airways controlled by tracheal intubation in the field.

Diagnosis

Brain Imaging

The first step in the diagnosis of SAH in the ED is non-contrast brain CT [1, 3, 8]. The CT in patients with

aneurysmal SAH will show blood (appears white) in the subarachnoid space, typically in the basal cisterns around the circle of Willis; major fissures; and occasionally isolated intraventricular location. Subarachnoid blood that is present high along the convexity is often due to non-aneurysmal causes, most commonly with head trauma. Less common causes include AVMs, cerebral amyloid angiopathy, vasculitis, and other toxic and inflammatory vasculopathies [12].

Negative CT scans can occur in several settings. The two most important bleeds are too small to be detectable and the bleeds that have occurred hours to days before the CT scan (CT is more sensitive soon after the bleed). The first factor is self-evident. The second, timing bias is due to the normal circulation of cerebrospinal fluid (CSF). Other possibilities include incorrect interpretation (CT is actually positive), patients whose hematocrits are ≤ 30 (blood is isodense with brain), and technical factors (poor CT quality) [3, 8].

Again, CT sensitivity drops over time [7]. Studies relying on older CT technology suggest that CT sensitivity is approximately 90 % on the day of the hemorrhage, falls to 60–85 % on day 5, and is approximately 50 % at one week. Modern scanners are likely more sensitive; however, in one recent study using multi-detector scans, CT sensitivity in SAH patients with a normal mental status was still only 91 % [13].

The normal volume of CSF present in the body (150 ml) turns over 3 times daily. This circulation accounts for the drop-off in CT sensitivity. One recent study suggests that CT was 100 % sensitive within 3 days of the headache onset [14]. However, nearly 60 % of patients in this referral to a neurosurgical center had SAH, so this was not a typical ED population in which one would expect an incidence of SAH between 8 and 12 % [3].

The last relevant article—a multi-center, ED-based study that has not yet been independently verified—suggests that CT is 100 % sensitive if performed within 6 h of headache onset [15]. Of the 240 of 3,132 (7.7 %) ED patients with headache in the study, CT was 93 % sensitive overall. However, of the 953 patients scanned within 6 h of headache onset, 121 had SAH (12.7 %). CT revealed the SAH in all of these early presenters.

CT Confirms SAH

Although there are rare occasions in which CT is falsely positive, patients whose CT shows SAH should be assumed to have SAH and managed accordingly [2, 3].

CT Negative for SAH/LP Positive

Based on current evidence, patients under evaluation for SAH whose CT scans are negative, equivocal, or

non-diagnostic should undergo lumbar puncture (LP) [1, 3, 8]. As with CT, CSF results are also time-dependent. Large amounts of red blood cells (generally in the thousands) are initially present but rapidly diminish with time (due to the circulatory cycle discussed in the “[Brain Imaging](#)” section above).

Xanthochromia—the yellowish discoloration of CSF that results from in vivo degradation of hemoglobin into bilirubin (as well as oxyhemoglobin and methemoglobin)—begins to develop and is nearly universally present by 12 h after the onset of the bleed [3]. It can be measured by visual inspection of the centrifuged CSF or by spectrophotometry.

Although some recommend that spectrophotometry can be used as a more sensitive method to detect xanthochromia, this method leads to a high proportion of false positives [16]. Further, nearly all hospital clinical laboratories in North America use visual inspection following sample centrifugation to assess xanthochromia [17]. Finally, CSF deemed “clear” by visual inspection is very unlikely to be compatible with SAH [18]; however, this visual inspection should be performed in a conical-base test tube (typically supplied in the LP kit) and not in a capillary tube. The tube of fluid should be compared with water against a white background in neutral lighting.

Measuring the opening pressure is recommended, and it will be elevated in approximately 2/3 of SAH cases [19]. The presence of elevated opening pressure may also help to distinguish traumatic taps from true SAH [20]. The best indicator is the absence of xanthochromia.

Alternative Diagnostic Pathways

Other diagnostic pathways have been suggested, including an LP-first strategy based on mathematical modeling that indicated improved resource management and a higher rate of LP (it should be noted that this method has not been clinically tested in the CT era) [21]. Another model includes the use of magnetic resonance imaging (MRI), which is quite sensitive for blood, including SAH, and is superior to CT in terms of timing the bleed. However, due to greater availability, lower cost, and greater experience with its interpretation, CT remains the recommended first test [1, 3]. If MRI is used as the initial imaging test, an LP is still necessary if the MRI is negative [1].

More recently, primary CT followed by CT angiography (CTA) has been suggested as a possible diagnostic pathway [22, 23]. Among other issues, however, the CT (if negative) followed by CTA will primarily diagnose an aneurysm as opposed to diagnosing a bleed. There are many downstream implications of this technique that clinicians should consider [24].

SAH Confirmed

Once SAH is confirmed by any means (CT, LP, or other), several management steps must be addressed. In addition to the specific steps below, the patient should be placed on bed rest with cardiac monitoring, and a 12-lead electrocardiogram should be obtained. Blood should be sent to the laboratory for a complete blood count as well as coagulation tests, electrolytes, renal function, and troponin.

Definitive therapy is the obliteration of the aneurysm, either by clipping or endovascular coiling; both of these isolate the aneurysm from the general circulation and should be carried out as soon as feasible [1]. Several studies have shown that patient outcomes are improved when they are treated at high volume centers defined as those that treat >35 cases per year [1, 25, 26]. Low volume centers should strongly consider transfer of the patient to a high volume center as soon as feasible. Ideally, pre-arranged transfer agreements should be in place.

Initial Orders

Once the diagnosis of SAH is made and the patient is stabilized, the physician should speak to a cerebrovascular specialist. The “[Communication](#)” section below (Table 2) includes the checklist of communications that should be discussed in this conversation.

In addition to the standard communication about a patient, the conversation should ideally include the clinical status of the patient (often measured using the Hunt and Hess or the World Federation of Neurological Surgeons scores), results of brain imaging and/or CSF analysis, airway status, and the presence or absence of hydrocephalus. The discussion should also include goals of BP control, review of administered medications for pain and anxiety, and treatments for rebleeding, seizure, and vasospasm prophylaxis, as well as which clinician will take responsibility for vascular imaging.

Airway: Need for Intubation

The determination to place an endotracheal intubation follows standard factors: ability of the patient to control his or her airway; hyperventilation or hypoxia resistant to supplemental oxygen; or anticipated clinical decompensation over time, especially if a transfer to another facility is involved (see the *Airway, Ventilation, and Sedation protocol*).

Seizure Prophylaxis

Fewer than 20 % of SAH patients have seizures, but when they occur, they can result in aneurysm rerupture and

increased intracranial pressure (ICP). Actual seizures should be treated with anti-convulsants, but prophylactic anti-convulsants are optional. Also, in patients with altered mental status, non-convulsive status epilepticus may be present, which can only be diagnosed by electroencephalography (EEG).

Both the AHA and NCS guidelines [1, 2] suggest consideration of anti-convulsants in the immediate post-hemorrhage period [1], while other experts recommend against this practice [27]. Here, a very short course (<7 days) of prophylactic anti-convulsant is recommended in the period following diagnosis and before definitive aneurysm treatment. As phenytoin may lead to worse long-term cognitive outcomes, use of a different drug, such as levetiracetam, could be considered.

Decline in Neurological Status

Some patients with SAH will experience an early deterioration in neurological status. It is important in these patients to consider the full differential diagnosis, since the causes, and thus treatments, will vary.

Reassessment of the vital signs and telemetry monitor is critical. New hypotension will decrease cerebral perfusion pressure. New hypoxia may result from neurogenic pulmonary edema. Arrhythmias may also lead to hypotension. Cardiovascular collapse could be the result of increasing hydrocephalus and or brain herniation (Cushing's response) or, infrequently, neurocardiogenic shock from Takasubu's syndrome or respiratory failure from neurogenic pulmonary edema. Physical examination may show further evidence of herniation or a new seizure requiring treatment.

A repeat CT scan is also necessary, as it may show herniation, ultra-early rebleeding, development of or increase in hydrocephalus, or, rarely, development of an intraparenchymal or subdural hematoma.

Coagulopathy

Coagulopathy should be treated (see the algorithms in the *Intracerebral Hemorrhage* protocol for more details). Warfarin therapy is the most common source of coagulopathy. Patients with an international normalized ration (INR) >1.4 should be treated with some combination of fresh frozen plasma, intravenous (IV) vitamin K, and prothrombin complex concentrates, depending upon many different factors. Low platelet count below 50,000 can be treated with platelet transfusions.

There are no specific management guidelines to address patients with SAH taking anti-platelet agents, such as clopidogrel or prasugrel. These agents can potentially

increase the risk and severity of aneurysm rupture. Moreover, profound platelet inhibition with clopidogrel has been associated with significant procedural related complications. Reversal with platelet transfusions and other hemostatic agents should consider risk benefit for the individual patient in consultation with local experts in coagulopathy management.

Treat Pain and Anxiety

In addition to a primary motive of achieving the patient's comfort, treatment of pain, vomiting, and anxiety is clinically important. Judicious amounts of short-acting IV analgesics, such as fentanyl, should be used to help the patient avoid straining, Valsalva, and stress. Treating vomiting with anti-emetics may also be helpful. If there is a significant component of anxiety, small doses of IV lorazepam may help. All of these steps may help to control the elevated BP. Over-medication, which could mask subtle mental status changes, should be avoided.

BP Management

AHA and Neurocritical Care Society guidelines [1, 2] acknowledge the lack of quality data about BP control in SAH patients and suggest only that the blood pressure should be monitored and controlled to "balance the risk of stroke, hypertension-associated rebleeding, and maintenance of the cerebral perfusion pressure" [1]. That said, retrospective data suggest a higher rate of rebleeding with systolic BPs above 160 mmHg.

Current guidelines suggest treating extreme hypertension in patients with an unsecured ruptured aneurysm. Modest BP (mean arterial pressure, or MAP, <110) does not require treatment. Pre-morbid BPs should be considered and used to inform the risks and benefits of treatment. Experts in the field use anti-hypertensive medications that are short acting, easily titratable, and can be administered as an IV drip to reduce the systolic pressure to below 160 mmHg, or the MAP <110, keeping in mind the principles mentioned-above.

Hydrocephalus

The clinician should carefully evaluate the CT scan for hydrocephalus, which occurs in up to 30 % of SAH patients in the first 3 days. This may be asymptomatic but is more often seen in severely affected patients. If the hydrocephalus is symptomatic, it can be treated with an external ventricular drain, although some data suggest that this may be associated with rebleeding [1]. In addition,

Table 2 Subarachnoid hemorrhage communication regarding assessment and referral

<input type="checkbox"/> Clinical presentation (level of consciousness, motor exam, pupils)
<input type="checkbox"/> WFNS and Hunt–Hess Grade
<input type="checkbox"/> Hydrocephalus present?
<input type="checkbox"/> Airway status
<input type="checkbox"/> Medications given, including sedatives, analgesics, seizure prophylaxis, anti-hypertensives, and nimodipine
<input type="checkbox"/> Coordination of other vascular imaging
<input type="checkbox"/> Results of initial imaging

comatose patients with hydrocephalus may have elevated ICP, so placement of a drain will not only reduce ICP by allowing draining of CSF, but it will also provide a means to monitor ICP throughout the hospitalization.

Anti-Fibrinolytic Agents

Prevention of rebleeding before definitive aneurysm treatment is an important strategy. In the past, when surgical treatment was delayed for weeks, pre-operative anti-fibrinolytic treatment was standard. Currently, early definitive treatment of the aneurysm is generally recommended [1]. Thus, there has been an increased interest in early, short-term anti-fibrinolytic treatment with either amino-epsilon caproic acid or tranexamic acid in situations, where surgical options are not readily available. One study of immediate use of tranexamic acid to SAH patients, most of whom were treated within 24 h, demonstrated an 80 % reduction in rebleeding before the definitive treatment [2, 28].

Calcium Channel Blockers

The use of oral (or per nasogastric tube) nimodipine has been shown in multiple randomized trials to decrease cerebral ischemia and improve overall outcomes of SAH patients [29]. This is not mediated by amelioration of angiographically documented vasospasm; rather, nimodipine works via a presumed cellular neuroprotective mechanism. Other IV calcium channel blockers, such as nicardipine, have not been shown to improve outcomes (although they do improve vasospasm) [27]. Caution should be exercised to avoid drops in BPs with all of these agents, including oral nimodipine.

Communication

When communicating to an accepting or referring physician about this patient, consider including the key elements listed in Table 2.

References

1. Connolly ES Jr, Rabinstein AA, Carhuapoma JR, et al. Guidelines for the management of aneurysmal subarachnoid hemorrhage: a guideline for healthcare professionals from the American Heart Association/American Stroke Association. *Stroke*. 2012;43:1711–37.
2. Diringer MN, Bleck TP, Claude Hemphill J Jr. Critical care management of patients following aneurysmal subarachnoid hemorrhage: recommendations from the Neurocritical Care Society's Multidisciplinary Consensus Conference. *Neurocrit Care*. 2011;15:211–40.
3. Edlow JA, Malek AM, Ogilvy CS. Aneurysmal subarachnoid hemorrhage: update for emergency physicians. *J Emerg Med*. 2008;34:237–51.
4. Linn FH, Wijdicks EF. Causes and management of thunderclap headache: a comprehensive review. *Neurologist*. 2002;8:279–89.
5. Schievink WI, Karemaker JM, Hageman LM, van der Werf DJ. Circumstances surrounding aneurysmal subarachnoid hemorrhage. *Surg Neurol*. 1989;32:266–72.
6. Pope JV, Edlow JA. Favorable response to analgesics does not predict a benign etiology of headache. *Headache*. 2008;48:944–50.
7. Edlow JA, Panagos PD, Godwin SA, Thomas TL, Decker WW. American College of Emergency Physicians. Clinical policy: critical issues in the evaluation and management of adult patients presenting to the emergency department with acute headache. *Ann Emerg Med*. 2008;52:407–36.
8. Edlow JA, Caplan LR. Avoiding pitfalls in the diagnosis of subarachnoid hemorrhage. *N Engl J Med*. 2000;342:29–36.
9. Vermeulen MJ, Schull MJ. Missed diagnosis of subarachnoid hemorrhage in the emergency department. *Stroke J Cereb Circ*. 2007;38:1216–21.
10. Kowalski RG, Claassen J, Kreiter KT, et al. Initial misdiagnosis and outcome after subarachnoid hemorrhage. *JAMA*. 2004;291:866–9.
11. Perry JJ, Stiell IG, Sivilotti ML, et al. High risk clinical characteristics for subarachnoid haemorrhage in patients with acute headache: prospective cohort study. *BMJ*. 2010;341:c5204.
12. Cuvinciu V, Viguier A, Calviere L, et al. Isolated acute non-traumatic cortical subarachnoid hemorrhage. *AJNR Am J Neuroradiol*. 2010;31:1355–62.
13. Byyny RL, Mower WR, Shum N, Gabayan GZ, Fang S, Baraff LJ. Sensitivity of noncontrast cranial computed tomography for the emergency department diagnosis of subarachnoid hemorrhage. *Ann Emerg Med*. 2008;51:697–703.
14. Cortnum S, Sorensen P, Jorgensen J. Determining the sensitivity of computed tomography scanning in early detection of subarachnoid hemorrhage. *Neurosurgery*. 2010;66:900–2 (discussion 3).
15. Perry JJ, Stiell IG, Sivilotti ML, et al. Sensitivity of computed tomography performed within six hours of onset of headache for diagnosis of subarachnoid haemorrhage: prospective cohort study. *BMJ*. 2011;343:d4277.
16. Perry JJ, Sivilotti ML, Stiell IG, et al. Should spectrophotometry be used to identify xanthochromia in the cerebrospinal fluid of alert patients suspected of having subarachnoid hemorrhage? *Stroke J Cereb Circ*. 2006;37:2467–72.
17. Edlow JA, Bruner KS, Horowitz GL. Xanthochromia. *Arch Pathol Lab Med*. 2002;126:413–5.
18. Linn FH, Voorbij HA, Rinkel GJ, Algra A, van Gijn J. Visual inspection versus spectrophotometry in detecting bilirubin in cerebrospinal fluid. *J Neurol Neurosurg Psychiatry*. 2005;76:1452–4.
19. Walton J. Subarachnoid hemorrhage. Edinburgh: E&S Livingstone, Ltd.; 1956.

20. Shah KH, Edlow JA. Distinguishing traumatic lumbar puncture from true subarachnoid hemorrhage. *J Emerg Med.* 2002; 23:67–74.
21. Schull MJ. Lumbar puncture first: an alternative model for the investigation of lone acute sudden headache. *Acad Emerg Med.* 1999;6:131–6.
22. Carstairs SD, Tanen DA, Duncan TD, et al. Computed tomographic angiography for the evaluation of aneurysmal subarachnoid hemorrhage. *Acad Emerg Med.* 2006;13:486–92.
23. McCormack RF, Hutson A. Can computed tomography angiography of the brain replace lumbar puncture in the evaluation of acute-onset headache after a negative noncontrast cranial computed tomography scan? *Acad Emerg Med.* 2010;17:444–51.
24. Edlow JA. What are the unintended consequences of changing the diagnostic paradigm for subarachnoid hemorrhage after brain computed tomography to computed tomographic angiography in place of lumbar puncture? *Acad Emerg Med.* 2010;17:991–5. discussion 6–7.
25. Bardach NS, Zhao S, Gress DR, Lawton MT, Johnston SC. Association between subarachnoid hemorrhage outcomes and number of cases treated at California hospitals. *Stroke J Cereb Circ.* 2002;33:1851–6.
26. Berman MF, Solomon RA, Mayer SA, Johnston SC, Yung PP. Impact of hospital-related factors on outcome after treatment of cerebral aneurysms. *Stroke J Cereb Circ.* 2003;34:2200–7.
27. Rabinstein AA, Lanzino G, Wijdicks EF. Multidisciplinary management and emerging therapeutic strategies in aneurysmal subarachnoid haemorrhage. *Lancet Neurol.* 2010;9:504–19.
28. Hillman J, Fridriksson S, Nilsson O, Yu Z, Saveland H, Jakobsson KE. Immediate administration of tranexamic acid and reduced incidence of early rebleeding after aneurysmal subarachnoid hemorrhage: a prospective randomized study. *J Neurosurg.* 2002;97:771–8.
29. Dorhout Mees SM, Rinkel GJ, Feigin VL, et al. Calcium antagonists for aneurysmal subarachnoid haemorrhage. *Cochrane Database Syst Rev.* 2007:CD000277.