

Variceal Bleeding in Liver Cirrhosis at the ICU: Sufficient Data to Treat Adrenal Insufficiency?*

Alexander Koch, MD
Frank Tacke, MD, PhD

Department of Medicine III
RWTH-University Hospital Aachen
Aachen, Germany

Critical illness–related corticosteroid insufficiency (CIRCI) is defined as a subnormal adrenal response to adrenocorticotropin in severe illness, resulting in inadequately low cortisol levels relative to the severity of disease and inflammation (1). Cortisol fulfills essential functions in critical illness, such as limiting excessive inflammation and regulating vascular tone (2). In fact, administration of low doses of hydrocortisone can stabilize hemodynamics in patients with sepsis and may help to reduce the amount of vasopressors needed, but analyses of available high-quality multicenter trials revealed no benefit on survival (3). Thus, current guidelines for the treatment of severe sepsis and septic shock recommend against the routine use of corticosteroids in sepsis (4). Patients with liver cirrhosis share many similarities with patients with sepsis in terms of hemodynamic alterations, including increased cardiac output, decreased peripheral vascular resistance, decreased mean arterial pressure, and hyporesponsiveness to vasopressors (5). Notably, adrenal dysfunction is common in patients with end-stage liver disease, especially in conditions of critical illness, and associated with adverse prognosis (6).

In this issue of *Critical Care Medicine*, Tsai et al (7) investigated CIRCI in a large group of patients with cirrhosis admitted to the ICU due to acute gastroesophageal variceal bleeding (GEVB). They prospectively studied adrenal function using short corticotropin stimulation test (SST) in 157 episodes of GEVB in 143 patients with cirrhosis. CIRCI occurred in 29.9% of patients, which is well in accordance with the anticipated prevalence in critically ill patients with cirrhosis (8). Independent predictors of CIRCI were shock, high-density lipoprotein (HDL) cholesterol, platelet count, and bacterial infection. These findings fit to current hypotheses on the mechanisms leading to CIRCI in cirrhosis (Fig. 1). On one hand, reduced hepatic synthesis of cholesterol and lipoproteins (such as HDL) may cause a lack of substrates for steroid synthesis in the adrenal glands; on the other hand, increased levels of endotoxins (bacterial infection or translocation due to GEVB) may

suppress adrenocorticotrophic hormone secretion from the pituitary gland (6). In addition, the hypovolemic shock owing to the acute hemorrhage itself may contribute to adrenal insufficiency (Fig. 1). CIRCI may therefore be viewed as a typical characteristic of either decompensation of advanced chronic liver disease or consequences of massive hemorrhage.

Not surprisingly, in the current study, cirrhotic patients with acute GEVB and CIRCI had higher rates of treatment failure (63.8% vs 10.9%, $p < 0.001$) and 6-week mortality than patients with normal adrenal function (42.6% vs 6.4%, $p < 0.001$). This emphasizes the prognostic impact of CIRCI for patients with cirrhosis at the ICU, as studied by many other groups before (6), now focusing on the specific subset of patients admitted with variceal bleeding. However, it needs to be pointed out that CIRCI was able to predict immediate treatment failure (within 5 days) but was not an independent predictor of 6-week mortality, unlike model of end-stage liver disease (MELD) score or infections. Thus, the clinical value of using SST for risk stratification is certainly rather limited. Many other powerful tools are available to predict the prognosis in patients with liver cirrhosis and GEVB, most of them using either modifications from the MELD score, lactate, or simple clinical assessments (9–11).

To our opinion, the true strength of the current study is that it provides a clear rationale for conducting a prospective randomized controlled trial in patients with cirrhosis bleeding from varices, in which CIRCI-positive patients are either supplemented by glucocorticoids or treated with placebo. A weakness of the current study, however, is that it does not allow to clearly dissect the main factor promoting CIRCI, cirrhosis versus bleeding/shock, in this high-risk patient population. Therefore, the exact target of a therapeutic intervention remains blurry. A limited number of small studies reported hydrocortisone therapy in patients with liver disease but yielded heterogeneous results. Although most studies confirmed hemodynamic stabilization in patients with cirrhosis receiving steroids, higher prevalence of infections and no clear benefit on survival were reported (6). Whereas early hemodynamic stabilization is a primary goal in patients with variceal bleeding at the ICU, infections are long known as a specific risk factor for the outcome in patients with cirrhosis and GEVB (12). The associations of CIRCI with shock, bacterial infection, and severity of liver disease, as identified in the current study, could possibly indicate that CIRCI may impact mortality through refractory shock and uncontrolled inflammation. Further interventional studies could specifically focus on these high-risk subgroups, namely patients with GEVB and shock, ongoing infection, and advanced-stage liver disease. Furthermore, the relevance of CIRCI for 5-day treatment failure, but not 6-week or long-term survival, suggest that a focused short-term steroid supplementation during acute hemodynamic instability might be most beneficial in this specific setting. Thus, future

*See also p. 2546.

Key Words: adrenal insufficiency; corticosteroids; gastrointestinal bleeding; intensive care unit; liver cirrhosis

The authors have disclosed that they do not have any potential conflicts of interest.

Copyright © 2014 by the Society of Critical Care Medicine and Lippincott Williams & Wilkins

DOI: 10.1097/CCM.0000000000000598

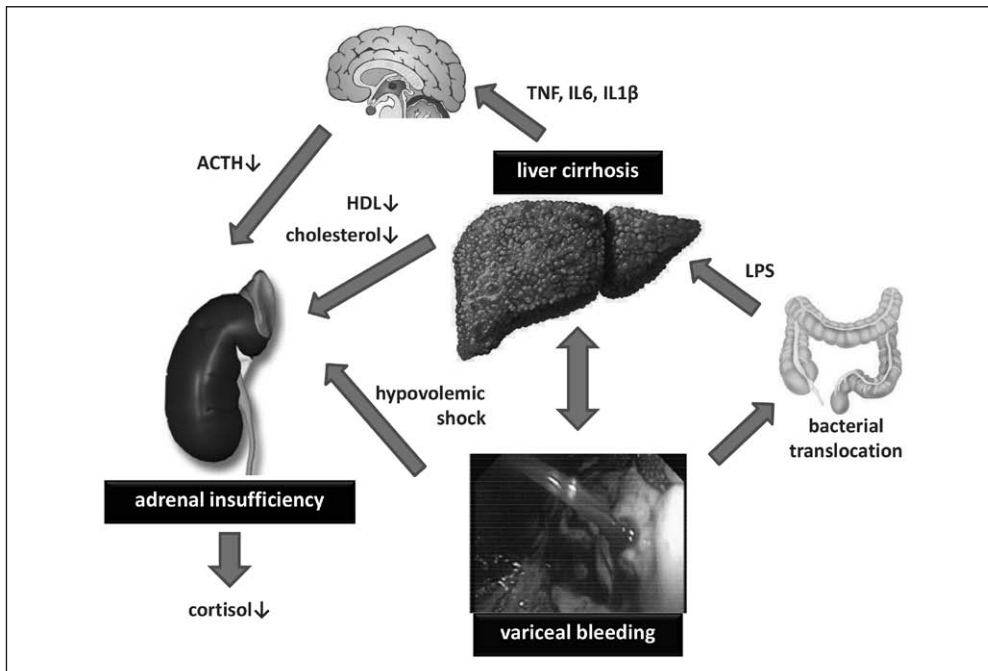


Figure 1. Critical illness–related corticosteroid insufficiency (CIRCI) in patients with liver cirrhosis and acute gastroesophageal variceal bleeding (schematic depiction). Both liver cirrhosis and hypovolemic shock due to acute hemorrhage may contribute to CIRCI. Increased levels of endotoxin (LPS, lipopolysaccharide) may lead to release of inflammatory cytokines, such as tumor necrosis factor (TNF), interleukin-1 (IL-1), or IL-6, which reduce secretion of adrenocorticotropic hormone (ACTH) from pituitary gland. Proportional to the extent of liver failure, cholesterol, high-density lipoprotein (HDL), and low-density lipoprotein cholesterol concentrations are reduced, which are required substrates for adrenal cortisol synthesis. Future studies are required to investigate the potential benefit of corticosteroid supplementation for the outcome of patients with cirrhosis and variceal bleeding.

interventional trials should aim at identifying the right treatment interval, the right dose, and the right patient subgroup for steroid supplementation in advanced liver disease with acute bleeding.

REFERENCES

1. Marik PE, Pastores SM, Annane D, et al; American College of Critical Care Medicine: Recommendations for the diagnosis and management of corticosteroid insufficiency in critically ill adult patients: Consensus statements from an international task force by the American College of Critical Care Medicine. *Crit Care Med* 2008; 36:1937–1949

2. Cooper MS, Stewart PM: Adrenal insufficiency in critical illness. *J Intensive Care Med* 2007; 22:348–362

3. Patel GP, Balk RA: Systemic steroids in severe sepsis and septic shock. *Am J Respir Crit Care Med* 2012; 185:133–139

4. Dellinger RP, Levy MM, Rhodes A, et al; Surviving Sepsis Campaign Guidelines Committee including the Pediatric Subgroup: Surviving sepsis campaign: International guidelines for management of severe sepsis and septic shock: 2012. *Crit Care Med* 2013; 41:580–637

5. Vincent JL, Gustot T: Sepsis and cirrhosis: Many similarities. *Acta Gastroenterol Belg* 2010; 73:472–478

6. Fede G, Spadaro L, Tomaselli T, et al: Adrenocortical dysfunction in liver disease: A systematic review. *Hepatology* 2012; 55:1282–1291

7. Tsai M-H, Huang H-C, Peng Y-S, et al: Critical Illness–Related Corticosteroid Insufficiency in Cirrhotic Patients With Acute Gastroesophageal Variceal Bleeding: Risk Factors and Association With Outcome. *Crit Care Med* 2014; 42: 2546–2555

8. Trifan A, Chiriac S, Stanciu C: Update on adrenal insufficiency in patients with liver cirrhosis. *World J Gastroenterol* 2013; 19:445–456

9. Reverer E, Tandon P, Augustin S, et al: A MELD-based model to determine risk of mortality among patients with acute variceal bleeding. *Gastroenterology* 2014; 146:412–419.e3

10. Tacke F, Fiedler K, Trautwein C: A simple clinical score predicts high risk for upper gastrointestinal hemorrhages from varices in patients with chronic liver disease. *Scand J Gastroenterol* 2007; 42:374–382

11. Koch A, Buendgens L, Dücker H, et al: [Gastrointestinal bleeding in liver cirrhosis at the ICU]. *Z Gastroenterol* 2013; 51:19–25

12. Jalan R, Gines P, Olson JC, et al: Acute-on chronic liver failure. *J Hepatol* 2012; 57:1336–1348